A 46-year-old woman comes to the clinic to establish primary care as a new patient. She is a marathon runner but has been unable to train due to a vertebral stress fracture diagnosed via x-ray during a recent emergency department visit. She has a history of hypothyroidism for which she takes levothyroxine. The patient's last menstrual period was a year ago. Her diet consists mainly of vegetables and fruit, and she takes a daily multivitamin. Her mother died of breast cancer at age 52. The patient is concerned that her family history puts her at risk for breast cancer. X-ray absorptiometry studies demonstrate abnormally low bone density in the lumbar vertebrae. Which of the following drugs is the most appropriate option for decreasing the risk of both bone fractures and breast cancer in this patient?

A. Alendronate
B. Ethinyl estradiol
C. Leuprolide
D. Medroxyprogesterone
E. Raloxifene
F. Tamoxifen

Submit

A 46-year-old woman comes to the clinic to establish primary care as a new patient. She is a marathon runner but has been unable to train due to a vertebral stress fracture diagnosed via x-ray during a recent emergency department visit. She has a history of hypothyroidism for which she takes levothyroxine. The patient's last menstrual period was a year ago. Her diet consists mainly of vegetables and fruit, and she takes a daily multivitamin. Her mother died of breast cancer at age 52. The patient is concerned that her family history puts her at risk for breast cancer. X-ray absorptiometry studies demonstrate abnormally low bone density in the lumbar vertebrae. Which of the following drugs is the most appropriate option for decreasing the risk of both bone fractures and breast cancer in this patient?

- A. Alendronate (6%)
- B. Ethinyl estradiol (4%)
- C. Leuprolide (1%)
- D. Medroxyprogesterone (2%)
- ✓ E. Raloxifene (62%)
- F. Tamoxifen (22%)

Omitted
Correct answer
E

62%
Answered correctly

17 secs
Time Spent

02/16/2020
Last Updated

Explanation

Selective estrogen receptor modulators	
	• Tamoxifen

Selective estrogen receptor modulators	
Drugs	• Tamoxifen • Raloxifene
Mechanism of action	• Competitive inhibitor of estrogen binding • Mixed agonist/antagonist action
Indications	• Prevention of breast cancer in high-risk patients • Tamoxifen: adjuvant treatment of breast cancer • Raloxifene: postmenopausal osteoporosis
Adverse effects	• Hot flashes • Venous thromboembolism • Endometrial hyperplasia & carcinoma (tamoxifen only)

This patient has amenorrhea and low bone density, suggesting a low-estrogen state. This may be due to menopause, although her exercise history suggests possible hypothalamic amenorrhea (excessive exercise suppresses secretion of GnRH, leading to decreased release of FSH and low estrogen levels). Because estrogen decreases bone resorption, estrogen deficiency in women increases the risk for osteoporosis. Although estrogen replacement therapy (eg, ethinyl estradiol) can mitigate this risk, it can increase the risk of breast cancer and should be avoided in patients with a family history of breast cancer **(Choice B)**. In addition, unopposed estrogen (ie, without concurrent progesterone) can cause endometrial proliferation resulting in endometrial hyperplasia and cancer.

Selective estrogen receptor modulators (eg, raloxifene, tamoxifen) are nonsteroidal compounds that bind estrogen receptors and exhibit **antagonist and agonist** properties in a **tissue-specific** manner. **Raloxifene** has estrogen agonist activity on bone, which decreases bone resorption, improves bone density, and decreases the risk of vertebral fractures. In addition, raloxifene has an estrogen antagonist effect on breast tissue and can decrease the risk of breast cancer. It also acts as an estrogen antagonist in the uterus and does not increase the risk of endometrial cancer.

Tamoxifen is a selective estrogen receptor modulator that has strong estrogen antagonist activity in the breast and is used in the treatment of

endometrial cancer.

Tamoxifen is a selective estrogen receptor modulator that has strong estrogen antagonist activity in the breast and is used in the treatment of estrogen receptor–positive breast cancer. It has estrogen-like effects on bone and can reduce the risk of osteoporosis in postmenopausal women. However, its agonist activity on the uterus increases the risk of endometrial hyperplasia/cancer and it is not appropriate for routine use in osteoporosis **(Choice F)**.

(Choice A) Bisphosphonates (eg, alendronate) inhibit osteoclast-mediated bone resorption. They have no estrogen agonist or antagonist activity and do not lower the risk of breast cancer.

(Choice C) Leuprolide is a GnRH analog that stimulates FSH and LH release (and subsequent estrogen production) when administered in a pulsatile manner (eg, via a programmable pump for treatment of anovulation) but suppresses release when administered continuously (eg, for endometriosis). Continuous use may reduce breast cancer risk but is associated with accelerated bone loss.

(Choice D) Medroxyprogesterone reduces the incidence of endometrial hyperplasia and endometrial carcinoma in postmenopausal women on estrogen replacement therapy, but otherwise has no benefit in management of osteoporosis. In addition, long-term use of medroxyprogesterone alone is associated with increased bone loss.

Educational objective:
Selective estrogen receptor modulators exhibit estrogen antagonist and agonist properties in a tissue-specific manner. Raloxifene has estrogen agonist activity on bone, which decreases bone resorption and improves bone density. Raloxifene has an estrogen antagonist effect on breast tissue and can decrease the risk of breast cancer; it also acts as an estrogen antagonist in the uterus, and does not increase the risk of endometrial cancer.

References

- Selective estrogen receptor modulators: tissue specificity and clinical utility.

Pharmacology	Rheumatology/Orthopedics & Sports	Osteoporosis
Subject	System	Topic

Copyright © UWorld. All rights reserved.

A 35-year-old man with a known history of peptic ulcer disease comes to the physician with sudden onset of pain, swelling, and redness at the base of his great toe. The patient was awakened in the middle of the night by the pain and was unable to go back to sleep. He has no history of trauma to the joint. Physical examination shows swelling, erythema, and exquisite tenderness involving the right first metatarsophalangeal joint. Fine-needle aspiration of the joint shows needle-shaped, negatively birefringent crystals. After making the diagnosis, the physician prescribes an appropriate medication. Shortly after starting the medication, the patient develops nausea, vomiting, and diarrhea. Which of the following is the most likely mechanism of action of the drug prescribed to this patient?

A. Decreased renal tubular uric acid reabsorption

B. Inhibition of cyclooxygenase activity

C. Inhibition of microtubule formation

D. Inhibition of phospholipase A_2 activity

E. Inhibition of xanthine oxidase activity

Submit

A 35-year-old man with a known history of peptic ulcer disease comes to the physician with sudden onset of pain, swelling, and redness at the base of his great toe. The patient was awakened in the middle of the night by the pain and was unable to go back to sleep. He has no history of trauma to the joint. Physical examination shows swelling, erythema, and exquisite tenderness involving the right first metatarsophalangeal joint. Fine-needle aspiration of the joint shows needle-shaped, negatively birefringent crystals. After making the diagnosis, the physician prescribes an appropriate medication. Shortly after starting the medication, the patient develops nausea, vomiting, and diarrhea. Which of the following is the most likely mechanism of action of the drug prescribed to this patient?

- A. Decreased renal tubular uric acid reabsorption (3%)
- B. Inhibition of cyclooxygenase activity (12%)
- ✓ C. Inhibition of microtubule formation (64%)
- D. Inhibition of phospholipase A_2 activity (1%)
- E. Inhibition of xanthine oxidase activity (17%)

Omitted
Correct answer
C

64%
Answered correctly

02 secs
Time Spent

05/09/2020
Last Updated

Explanation

Acute gouty arthritis	
	• Usually involves **first metatarsophalangeal**

Acute gouty arthritis	
Signs & symptoms	• Usually involves **first metatarsophalangeal joint** or knee • Swelling, erythema & **exquisite tenderness** • Symptoms develop rapidly over 24 hours
Diagnosis	• Joint aspiration shows **needle-shaped, negatively birefringent crystals**
Treatment	• Nonsteroidal anti-inflammatory drugs (eg, naproxen, indomethacin) preferred if no contraindications • Colchicine used as second-line therapy

©UWorld

Acute onset of pain and swelling of the first metatarsophalangeal joint and joint aspiration showing needle-shaped, negatively birefringent crystals are diagnostic for acute gouty arthritis. Nonsteroidal anti-inflammatory drugs (NSAIDs) are the mainstay of treatment for most patients. However, colchicine is often used in patients with mild-to-moderate renal failure, peptic ulcer disease, or other contraindications to NSAIDs. Colchicine is an effective anti-inflammatory agent in acute gouty arthritis and acts by binding to the intracellular protein tubulin, preventing tubulin polymerization into microtubules. This leads to impaired leukocyte migration and phagocytosis, reducing the inflammation seen in gouty arthritis. Because colchicine also disrupts microtubule formation in gastrointestinal mucosal cells, many patients develop diarrhea and, less commonly, nausea, vomiting, and abdominal pain.

(Choices A and E) Probenecid decreases proximal tubular uric acid reabsorption, and allopurinol inhibits xanthine oxidase (converts xanthine to uric acid). These medications are prescribed to lower serum uric acid levels in chronic gout. These agents are contraindicated in acute gouty

Acute onset of pain and swelling of the first metatarsophalangeal joint and joint aspiration showing needle-shaped, negatively birefringent crystals are diagnostic for acute gouty arthritis. Nonsteroidal anti-inflammatory drugs (NSAIDs) are the mainstay of treatment for most patients. However, colchicine is often used in patients with mild-to-moderate renal failure, peptic ulcer disease, or other contraindications to NSAIDs. Colchicine is an effective anti-inflammatory agent in acute gouty arthritis and acts by binding to the intracellular protein tubulin, preventing tubulin polymerization into microtubules. This leads to impaired leukocyte migration and phagocytosis, reducing the inflammation seen in gouty arthritis. Because colchicine also disrupts microtubule formation in gastrointestinal mucosal cells, many patients develop diarrhea and, less commonly, nausea, vomiting, and abdominal pain.

(Choices A and E) Probenecid decreases proximal tubular uric acid reabsorption, and allopurinol inhibits xanthine oxidase (converts xanthine to uric acid). These medications are prescribed to lower serum uric acid levels in chronic gout. These agents are contraindicated in acute gouty arthritis as they can mobilize tissue stores of uric acid and precipitate or worsen acute attacks.

(Choice B) NSAIDs induce their anti-inflammatory effects by inhibiting cyclooxygenase (COX)-1 and COX-2 isoenzymes, thus blocking prostaglandin synthesis. Because they can cause significant gastrointestinal irritation (eg, nausea, dyspepsia, bleeding), their use is contraindicated in patients with peptic ulcer disease.

(Choice D) Glucocorticosteroids exert their anti-inflammatory effect by inhibiting phospholipase A_2 activity. These medications can be used in acute gout and are not associated with significant diarrhea.

Educational objective:
Colchicine is a second-line agent for treating acute gouty arthritis. It inhibits tubulin polymerization and microtubule formation in leukocytes, reducing neutrophil chemotaxis and emigration to sites inflamed by tissue deposition of monosodium urate crystals. Gastrointestinal mucosal function is also impaired by microtubule disruption, leading to diarrhea and, less commonly, nausea, vomiting, and abdominal pain.

References

- Safety profile of anti-gout agents: an update.

Pharmacology	Rheumatology/Orthopedics & Sports	Gout
Subject	System	Topic

A 55-year-old man comes to the emergency department with severe right foot pain that started suddenly in the middle of the night. He has never had such symptoms before. He has a history of diet-controlled type 2 diabetes mellitus. His BMI is 32 kg/m^2. Physical examination shows swelling and tenderness of the first metatarsophalangeal joint. His leukocyte count is 13,500/μL and serum creatinine is 0.8 mg/dL. Joint aspiration is performed, and synovial fluid microscopic findings are shown in the image below.

Which of the following is the best initial treatment for this patient?

- A. Cyclooxygenase inhibitor
- B. Lipoxygenase inhibitor
- C. Oral glucocorticoid
- D. Systemic antibiotics
- E. TNF-alpha inhibitor
- F. Uricosuric agent
- G. Xanthine oxidase inhibitor

Submit

A 55-year-old man comes to the emergency department with severe right foot pain that started suddenly in the middle of the night. He has never had such symptoms before. He has a history of diet-controlled type 2 diabetes mellitus. His BMI is 32 kg/m^2. Physical examination shows swelling and tenderness of the first metatarsophalangeal joint. His leukocyte count is 13,500/μL and serum creatinine is 0.8 mg/dL. Joint aspiration is performed, and synovial fluid microscopic findings are shown in the image below.

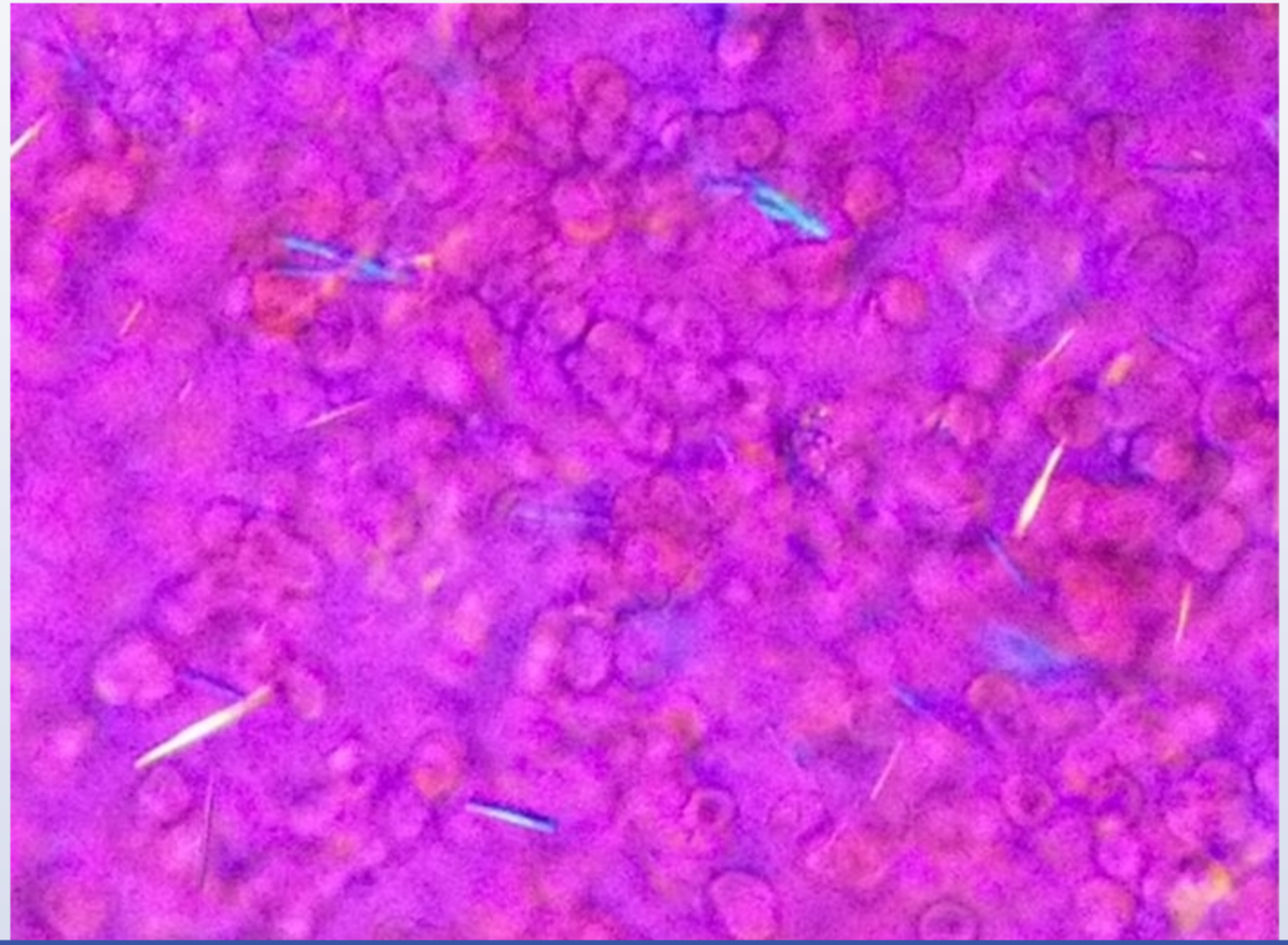

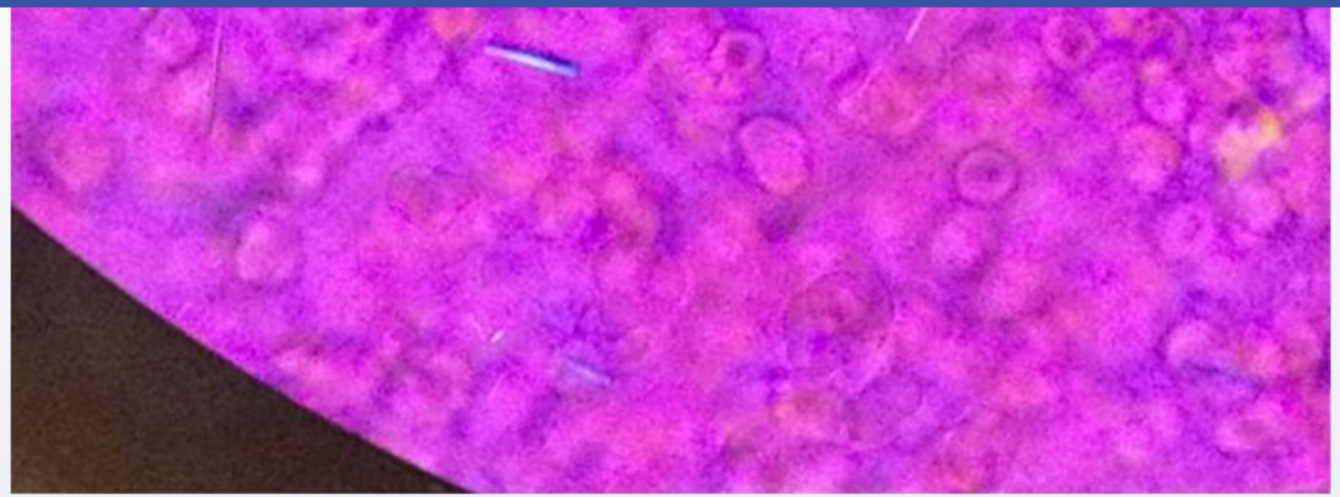

Which of the following is the best initial treatment for this patient?

- A. Cyclooxygenase inhibitor
- B. Lipoxygenase inhibitor
- C. Oral glucocorticoid
- D. Systemic antibiotics
- E. TNF-alpha inhibitor
- F. Uricosuric agent
- G. Xanthine oxidase inhibitor

Submit

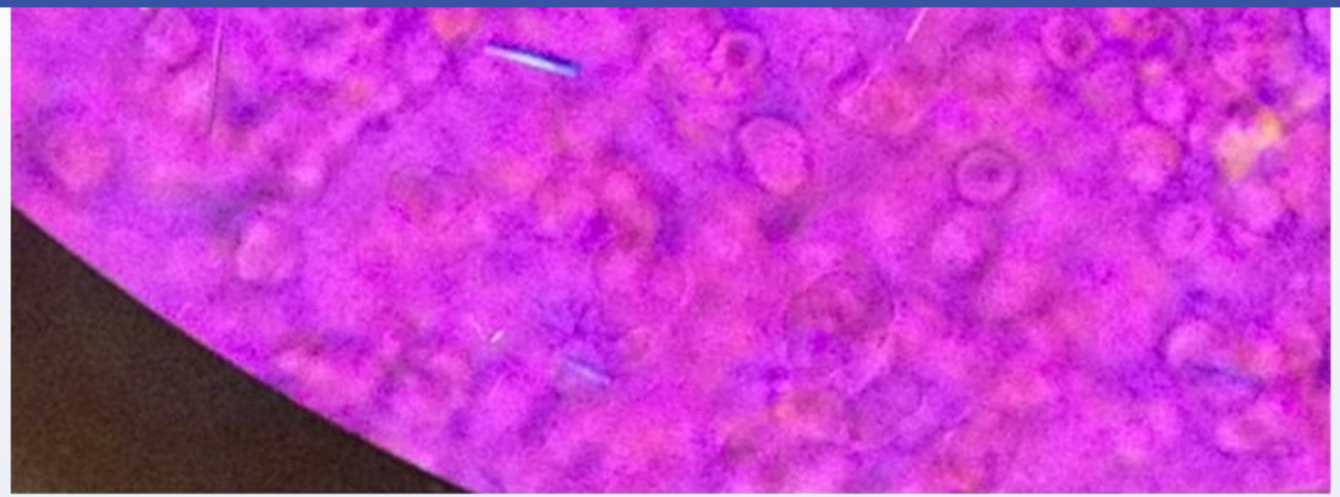

Which of the following is the best initial treatment for this patient?

- ✓ A. Cyclooxygenase inhibitor (68%)
- B. Lipoxygenase inhibitor (0%)
- C. Oral glucocorticoid (9%)
- D. Systemic antibiotics (0%)
- E. TNF-alpha inhibitor (0%)
- F. Uricosuric agent (4%)
- G. Xanthine oxidase inhibitor (15%)

Omitted
Correct answer

68%
Answered correctly

05 secs
Time Spent

06/13/2020
Last Updated

Explanation

Acute gouty arthritis	
Signs & symptoms	• Usually involves **first metatarsophalangeal joint** or knee • Swelling, erythema & **exquisite tenderness** • Symptoms develop rapidly over 24 hours
Diagnosis	• Joint aspiration shows **needle-shaped, negatively birefringent crystals**
Treatment	• Nonsteroidal anti-inflammatory drugs (eg, naproxen, indomethacin) preferred if no contraindications • Colchicine used as second-line therapy

©UWorld

Synovial fluid analysis in this patient with acute monoarthritis shows needle-shaped, negatively birefringent crystals (ie, monosodium urate crystals) under polarized light, which are diagnostic for **gout**. Phagocytosis of urate crystals by neutrophils causes the release of various cytokines and inflammatory mediators that lead to further neutrophil activation and chemotaxis, resulting in a positive feedback loop that amplifies the inflammatory response.

Nonsteroidal anti-inflammatory drugs (NSAIDs) are the first-line treatment for most patients with acute gouty arthritis. They inhibit cyclooxygenase enzymes and therefore decrease prostaglandin synthesis and exert a broad anti-inflammatory effect that includes inhibition of neutrophils. NSAIDs should be avoided in patients with renal and hepatic dysfunction or those at high risk for peptic ulcer.

Synovial fluid analysis in this patient with acute monoarthritis shows needle-shaped, negatively birefringent crystals (ie, monosodium urate crystals) under polarized light, which are diagnostic for **gout**. Phagocytosis of urate crystals by neutrophils causes the release of various cytokines and inflammatory mediators that lead to further neutrophil activation and chemotaxis, resulting in a positive feedback loop that amplifies the inflammatory response.

Nonsteroidal anti-inflammatory drugs (NSAIDs) are the first-line treatment for most patients with acute gouty arthritis. They inhibit cyclooxygenase enzymes and therefore decrease prostaglandin synthesis and exert a broad anti-inflammatory effect that includes inhibition of neutrophils. NSAIDs should be avoided in patients with renal and hepatic dysfunction or those at high risk for peptic ulcer.

(Choice B) Lipoxygenase inhibitors (eg, zileuton) decrease production of pro-inflammatory leukotrienes and are indicated for treatment of asthma. Lipoxygenase inhibitors are not useful in the treatment of acute or chronic gout.

(Choice C) Glucocorticoid therapy, either systemic or intraarticular, is used in patients with contraindications to both NSAIDs and colchicine (eg, renal dysfunction, the elderly). In addition, this patient has diabetes mellitus, and glucocorticoid use will increase his blood glucose levels.

(Choice D) Antibiotics are used in patients with acute septic arthritis. Synovial fluid analysis in septic arthritis will show bacteria and a high concentration of leukocytes.

(Choice E) TNF-alpha inhibitors (eg, infliximab, etanercept) are used as disease-modifying agents in rheumatoid arthritis.

(Choices F and G) Uric acid-lowering therapy with uricosuric agents (eg, probenecid) or xanthine oxidase inhibitors (eg, allopurinol, febuxostat) is used to prevent acute attacks in patients with recurrent and progressive gouty arthritis and those with macroscopic tophi. These drugs should **not** be initiated during an acute gout attack as they can exacerbate acute arthritis.

Educational objective:
Nonsteroidal anti-inflammatory drugs are the first-line treatment for acute gouty arthritis. They inhibit cyclooxygenase and therefore decrease prostaglandin synthesis and exert a broad anti-inflammatory effect that includes inhibition of neutrophils.

References

- Treatment of acute gout: a systematic review.

Exhibit Display



Zoom In
Zoom Out
Reset
Add To New Card | Existing Card

1
2
3
4
5
6
7
8
9
10
11
12
13
14
15
16
17
18
19
20

Exhibit Display

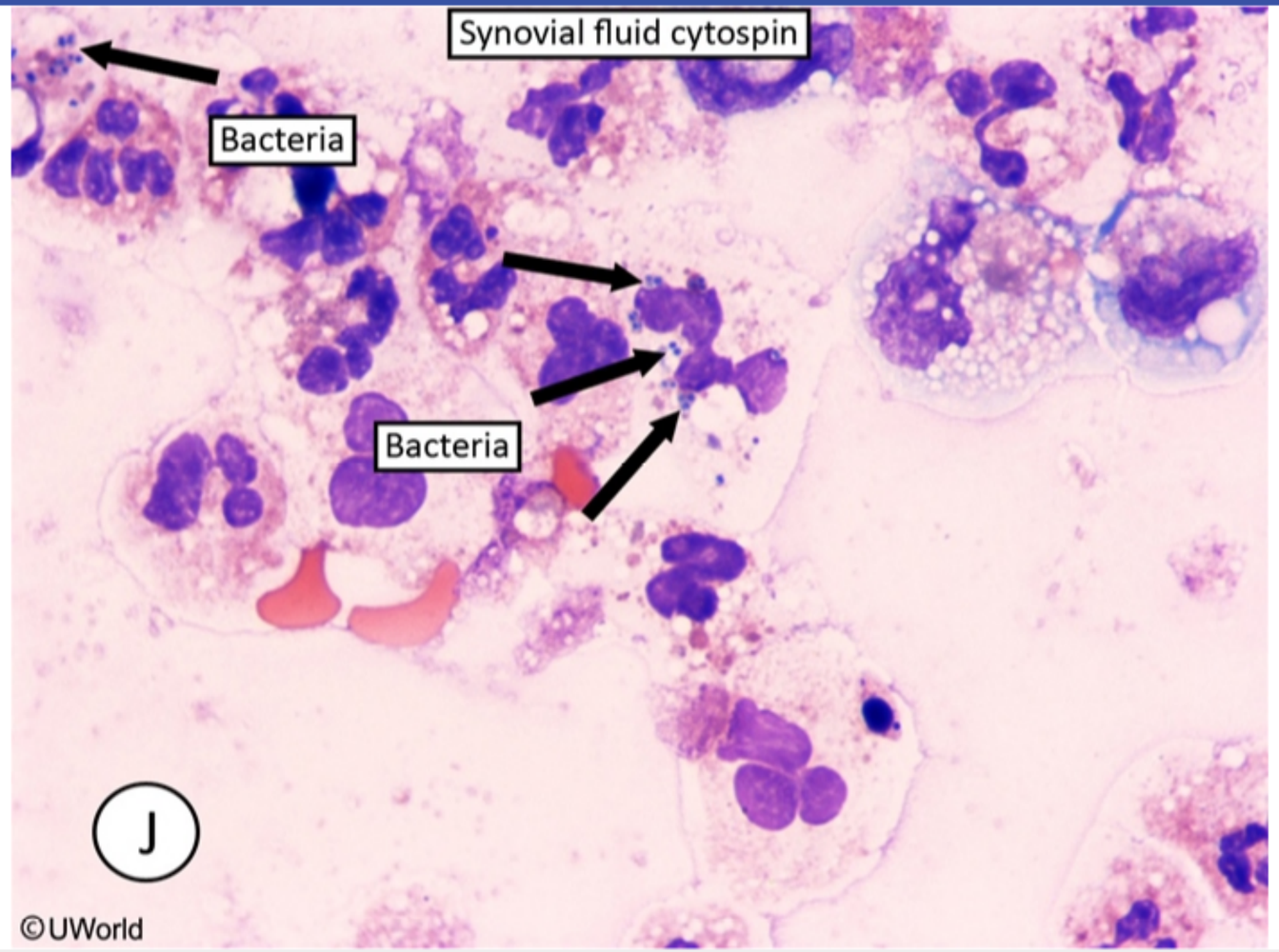

Zoom In | Zoom Out | Reset | Add To New Card | Existing Card

Exhibit Display

Zoom In
Zoom Out
Reset
Add To New Card | Existing Card

A 65-year-old woman is concerned about her risk of fracture as her mother was recently hospitalized for osteoporotic hip fracture. The patient walks her dog for a mile on most days and has no problems with balance or falling. She has a history of hypertension, hyperlipidemia, coronary artery disease, seizure disorder, and gastroesophageal reflux disease. The patient underwent menopause at age 52. She has smoked a pack of cigarettes daily for 24 years but does not drink alcohol. Weight is 56 kg (123.5 lb). Long-term use of which of the following medications may increase this patient's risk of osteoporosis and hip fracture?

A. Atorvastatin
B. Chlorthalidone
C. Levetiracetam
D. Metoprolol
E. Nitroglycerin
F. Omeprazole

Submit

A 65-year-old woman is concerned about her risk of fracture as her mother was recently hospitalized for osteoporotic hip fracture. The patient walks her dog for a mile on most days and has no problems with balance or falling. She has a history of hypertension, hyperlipidemia, coronary artery disease, seizure disorder, and gastroesophageal reflux disease. The patient underwent menopause at age 52. She has smoked a pack of cigarettes daily for 24 years but does not drink alcohol. Weight is 56 kg (123.5 lb). Long-term use of which of the following medications may increase this patient's risk of osteoporosis and hip fracture?

- A. Atorvastatin (5%)
- B. Chlorthalidone (15%)
- C. Levetiracetam (11%)
- D. Metoprolol (1%)
- E. Nitroglycerin (0%)
- ✓ F. Omeprazole (65%)

Omitted
Correct answer
F

65%
Answered correctly

02 secs
Time Spent

03/06/2020
Last Updated

Explanation

Medications associated with osteoporotic fractures	
Medication	Possible mechanism

Medications associated with osteoporotic fractures	
Medication	**Possible mechanism**
Anticonvulsants that induce cytochrome P450 (phenobarbital, phenytoin, carbamazepine)	↑ Vitamin D catabolism
Aromatase inhibitors	↓ Estrogen
Medroxyprogesterone	
GnRH agonists	↓ Testosterone & estrogen
Proton pump inhibitors	↓ Calcium absorption
Glucocorticoids	↓ Bone formation

Insoluble calcium (eg, calcium carbonate) requires an acidic environment for proper absorption. Strong acid-suppressing medications, such as **proton pump inhibitors** (eg, omeprazole), may **decrease absorption of dietary calcium** in the gastrointestinal tract. Long-term use of these medications is associated with an increased risk of **osteoporotic fractures**. The risk is greatest in older adults in whom calcium absorption is already reduced and in those with other risk factors for osteoporosis (eg, low body weight, smoking).

Medications that reduce bone formation (eg, glucocorticoids) can also increase the risk of osteoporosis. Because estrogen plays an important role in bone density, medications that decrease estrogen production (eg, aromatase inhibitors, GnRH agonists) can increase osteoporosis risk. In addition, anticonvulsants that induce the cytochrome P450 system in the liver (eg, phenytoin, carbamazepine) can increase catabolism of vitamin D and lead to lower bone density. Levetiracetam does not induce the P450 enzyme system and has not been shown to negatively affect bone mineral density in adults **(Choice C)**.

(Choice A) Statins (eg, atorvastatin) do not increase the risk of osteoporosis, and some studies have noted increased bone density in patients taking these medications.

(Choice B) Thiazide diuretics (eg, chlorthalidone, hydrochlorothiazide) increase reabsorption of calcium in the distal renal tubule and are associated with a small decrease in the risk of osteoporosis.

insoluble calcium (eg, calcium carbonate) requires an acidic environment for proper absorption. Strong acid-suppressing medications, such as **proton pump inhibitors** (eg, omeprazole), may **decrease absorption of dietary calcium** in the gastrointestinal tract. Long-term use of these medications is associated with an increased risk of **osteoporotic fractures**. The risk is greatest in older adults in whom calcium absorption is already reduced and in those with other risk factors for osteoporosis (eg, low body weight, smoking).

Medications that reduce bone formation (eg, glucocorticoids) can also increase the risk of osteoporosis. Because estrogen plays an important role in bone density, medications that decrease estrogen production (eg, aromatase inhibitors, GnRH agonists) can increase osteoporosis risk. In addition, anticonvulsants that induce the cytochrome P450 system in the liver (eg, phenytoin, carbamazepine) can increase catabolism of vitamin D and lead to lower bone density. Levetiracetam does not induce the P450 enzyme system and has not been shown to negatively affect bone mineral density in adults **(Choice C)**.

(Choice A) Statins (eg, atorvastatin) do not increase the risk of osteoporosis, and some studies have noted increased bone density in patients taking these medications.

(Choice B) Thiazide diuretics (eg, chlorthalidone, hydrochlorothiazide) increase reabsorption of calcium in the distal renal tubule and are associated with a small decrease in the risk of osteoporosis.

(Choice D) Beta blockers (eg, metoprolol) may slightly decrease the risk of osteoporosis, possibly due to increased formation and decreased resorption of bone.

(Choice E) Nitrates (eg, nitroglycerin) have been associated in some studies with increased bone density, possibly due to decreased bone turnover.

Educational objective:
Long-term acid suppression with proton pump inhibitors may be associated with an increased risk of osteoporotic fractures, possibly due to decreased calcium absorption. Other medications associated with an increased risk of osteoporosis include glucocorticoids, aromatase inhibitors, and anticonvulsants that induce cytochrome P450.

References

- Update on medications with adverse skeletal effects.
- Study of the association between hip fracture and acid-suppressive drug use in a UK primary care setting.
- Drug-induced osteoporosis: mechanisms and clinical implications.

A 58-year-old woman comes to the emergency department due to sudden-onset, severe back pain. The patient has had no major trauma; the pain started after she sat down too quickly on a hardwood chair. She has no leg weakness or numbness. The patient has a long history of hypothyroidism and rheumatoid arthritis treated with several medications over many years. Examination shows point tenderness over the mid thoracic spine. The straight leg raising test is negative and lower extremity neurologic examination shows no abnormalities. Spine imaging is shown below.

Which of the following could have prevented this patient's current condition?

A. Avoiding the use of glucocorticoids

Which of the following could have prevented this patient's current condition?

- A. Avoiding the use of glucocorticoids
- B. Decreasing the use of methotrexate
- C. Limiting the use of indomethacin
- D. Reducing the use of bisphosphonate
- E. Taking a higher dose of levothyroxine
- F. Using a proton pump inhibitor

Submit

Which of the following could have prevented this patient's current condition?

- A. Avoiding the use of glucocorticoids (88%)
- B. Decreasing the use of methotrexate (4%)
- C. Limiting the use of indomethacin (0%)
- D. Reducing the use of bisphosphonate (3%)
- E. Taking a higher dose of levothyroxine (2%)
- F. Using a proton pump inhibitor (0%)

Omitted
Correct answer

88%
Answered correctly

07 secs
Time Spent

02/23/2020
Last Updated

Medications associated with osteoporotic fractures	
Medication	**Possible mechanism**
Anticonvulsants that induce cytochrome P450 (phenobarbital, phenytoin, carbamazepine)	↑ Vitamin D catabolism
Aromatase inhibitors	↓ Estrogen
Medroxyprogesterone	
GnRH agonists	↓ Testosterone & estrogen
Proton pump inhibitors	↓ Calcium absorption
Glucocorticoids	↓ Bone formation

This patient has a fragility fracture of a thoracic vertebra, defined as a fracture due to a force significantly less than that required to fracture a normal bone. A fragility fracture suggests underlying bone pathology, often due to metastatic malignancy or intrinsic bone disease.

Chronic or recurrent **glucocorticoid** (eg, prednisone) use, as is occasionally needed in patients with rheumatoid arthritis, is associated with an increased risk for **osteoporosis**. Osteoporosis can also occur due to systemic absorption of topical glucocorticoids (eg, inhaled glucocorticoids used in the treatment of asthma). Glucocorticoids promote osteoporosis by increasing osteoclast differentiation and activity, decreasing osteoblast activity and synthesis of bone matrix, and inhibiting intestinal calcium absorption.

(Choices B and C) Methotrexate can cause bone marrow suppression, hepatotoxicity, stomatitis, and interstitial pneumonitis. Nonsteroidal anti-inflammatory drugs (NSAIDs; eg, indomethacin) cause renal impairment and peptic ulcers. Methotrexate and NSAIDs are not known to cause osteoporosis.

(Choice D) Osteonecrosis (ie, avascular necrosis) of the jaw is an adverse effect of bisphosphonates used in the treatment of osteoporosis. Chronic glucocorticoid use can also cause osteonecrosis, but this primarily involves the femoral head (vertebral involvement is uncommon).

(Choice E) Hyperthyroidism or over replacement of thyroid hormone in patients with hypothyroidism increases bone turnover and can lead to

This patient has a fragility fracture of a thoracic vertebra, defined as a fracture due to a force significantly less than that required to fracture a normal bone. A fragility fracture suggests underlying bone pathology, often due to metastatic malignancy or intrinsic bone disease.

Chronic or recurrent **glucocorticoid** (eg, prednisone) use, as is occasionally needed in patients with rheumatoid arthritis, is associated with an increased risk for **osteoporosis**. Osteoporosis can also occur due to systemic absorption of topical glucocorticoids (eg, inhaled glucocorticoids used in the treatment of asthma). Glucocorticoids promote osteoporosis by increasing osteoclast differentiation and activity, decreasing osteoblast activity and synthesis of bone matrix, and inhibiting intestinal calcium absorption.

(Choices B and C) Methotrexate can cause bone marrow suppression, hepatotoxicity, stomatitis, and interstitial pneumonitis. Nonsteroidal anti-inflammatory drugs (NSAIDs; eg, indomethacin) cause renal impairment and peptic ulcers. Methotrexate and NSAIDs are not known to cause osteoporosis.

(Choice D) Osteonecrosis (ie, avascular necrosis) of the jaw is an adverse effect of bisphosphonates used in the treatment of osteoporosis. Chronic glucocorticoid use can also cause osteonecrosis, but this primarily involves the femoral head (vertebral involvement is uncommon).

(Choice E) Hyperthyroidism or over-replacement of thyroid hormone in patients with hypothyroidism increases bone turnover and can lead to osteoporosis. Undertreatment is not associated with osteoporosis.

(Choice F) Proton pump inhibitors (eg, omeprazole) decrease gastric acid secretion and are commonly used in the treatment of gastroesophageal reflux disease. They also reduce the risk of peptic ulcer due to NSAIDs. However, proton pump inhibitors increase the risk of osteoporosis, possibly due to decreased intestinal calcium absorption.

Educational objective:
Osteoporosis is a common cause of fragility fractures, which occur in the absence of significant trauma. Chronic, systemic use of glucocorticoids such as prednisone promotes osteoporosis and increases the risk of fractures.

References

- Approach to the patient with secondary osteoporosis.
- Management of glucocorticoid-induced osteoporosis: prevalence, and emerging treatment options.

1
2
3
4
5
6
7
8
9
10
11
12
13
14
15
16
17
18
19
20

Exhibit Display

Zoom In | Zoom Out | Reset | Add To New Card | Existing Card

A 45-year-old woman comes to the office due to gradually progressive pain, stiffness, and swelling of her hand joints for the past several months. The patient has had prolonged morning stiffness and significant restriction of her daily activities due to the pain, as well as generalized fatigue. She describes the symptoms over the last several weeks as "disabling," and she needs assistance with activities of daily living in the morning. The patient has tried over-the-counter pain medications, such as acetaminophen and ibuprofen, with only minimal relief of her symptoms. She has no other medical problems. Family history is significant for diabetes mellitus on her maternal side. Which of the following drugs would provide the most rapid relief of her symptoms?

- A. Colchicine
- B. Hydroxychloroquine
- C. Methotrexate
- D. Minocycline
- E. Prednisone
- F. Sulfasalazine

Submit

A 45-year-old woman comes to the office due to gradually progressive pain, stiffness, and swelling of her hand joints for the past several months. The patient has had prolonged morning stiffness and significant restriction of her daily activities due to the pain, as well as generalized fatigue. She describes the symptoms over the last several weeks as "disabling," and she needs assistance with activities of daily living in the morning. The patient has tried over-the-counter pain medications, such as acetaminophen and ibuprofen, with only minimal relief of her symptoms. She has no other medical problems. Family history is significant for diabetes mellitus on her maternal side. Which of the following drugs would provide the most rapid relief of her symptoms?

A. Colchicine (7%)
B. Hydroxychloroquine (2%)
C. Methotrexate (23%)
D. Minocycline (0%)
✓ E. Prednisone (63%)
F. Sulfasalazine (3%)

Omitted
Correct answer
E

63%
Answered correctly

02 secs
Time Spent

01/19/2020
Last Updated

Explanation

This patient has swelling, pain, and morning stiffness in multiple joints for >6 weeks, consistent with **rheumatoid arthritis** (RA). The foundation of management for RA is **disease-modifying antirheumatic drugs (DMARDs)**, which alleviate pain and inflammation and reduce long-term joint destruction and disability. Examples of DMARDS are methotrexate (typically first-line), sulfasalazine, hydroxychloroquine, minocycline, and tumor

This patient has swelling, pain, and morning stiffness in multiple joints for >6 weeks, consistent with **rheumatoid arthritis** (RA). The foundation of management for RA is **disease-modifying antirheumatic drugs (DMARDs)**, which alleviate pain and inflammation and reduce long-term joint destruction and disability. Examples of DMARDS are methotrexate (typically first-line), sulfasalazine, hydroxychloroquine, minocycline, and tumor necrosis factor-alpha inhibitors.

However, the response to DMARD therapy typically takes weeks **(Choices B, C, D, and F)**. Therefore, short-term treatment with anti-inflammatory therapies, including systemic and intraarticular **glucocorticoids** (eg, prednisone) or **nonsteroidal anti-inflammatory drugs** (NSAIDs), can provide rapid, temporary relief of symptoms in patients starting on DMARDs. However, they do not provide adequate long-term control of disease or prevention of joint deformity.

Glucocorticoids exert their anti-inflammatory effects by inhibiting phospholipase A2, which decreases prostaglandin and leukotriene synthesis. Glucocorticoids also depress the immune response by inhibiting the transcription of multiple cytokines and adhesion proteins, which reduces leukocyte recruitment and activation.

(Choice A) Colchicine is used in the management of both acute and chronic gout. Colchicine works by binding to tubulin and inhibiting microtubule polymerization. This results in disruption of neutrophil chemotaxis and phagocytosis, thereby reducing the inflammatory response to uric acid crystals. Colchicine is not effective in RA.

Educational objective:
The foundation of management for rheumatoid arthritis is disease-modifying antirheumatic drugs, which alleviate pain and inflammation and reduce long-term joint destruction. However, the response to treatment may take several weeks. Nonsteroidal anti-inflammatory drugs and glucocorticoids can provide rapid symptom relief in the interim.

References

- Efficacy of prednisone 1-4 mg/day in patients with rheumatoid arthritis: a randomised, double-blind, placebo controlled withdrawal clinical trial.

Pharmacology	Rheumatology/Orthopedics & Sports	Rheumatoid arthritis
Subject	System	Topic

Copyright © UWorld. All rights reserved.

A 78-year-old woman comes to the emergency department due to acute vision loss. She had rapid-onset monocular vision loss in the left eye that developed over an hour. There is no associated pain in the eye, but the patient has had left-sided headaches most days for the last 3 weeks. She also has had achy pain in the shoulders that has slowly worsened over the last month. Examination shows decreased pupillary light reflex in the left eye with severely impaired visual acuity. Which of the following is the most appropriate treatment for this patient's condition?

A. Acetazolamide

B. Clopidogrel

C. Ganciclovir

D. Methylprednisolone

E. Sumatriptan

Submit

A 78-year-old woman comes to the emergency department due to acute vision loss. She had rapid-onset monocular vision loss in the left eye that developed over an hour. There is no associated pain in the eye, but the patient has had left-sided headaches most days for the last 3 weeks. She also has had achy pain in the shoulders that has slowly worsened over the last month. Examination shows decreased pupillary light reflex in the left eye with severely impaired visual acuity. Which of the following is the most appropriate treatment for this patient's condition?

- A. Acetazolamide (10%)
- B. Clopidogrel (5%)
- C. Ganciclovir (1%)
- ✓ D. Methylprednisolone (75%)
- E. Sumatriptan (6%)

Omitted
Correct answer
D

75%
Answered correctly

01 sec
Time Spent

02/04/2020
Last Updated

Explanation

Giant cell arteritis	
Symptoms	• Systemic: fever, fatigue, malaise, weight loss • Headache • Jaw claudication • Visual disturbances (eg, ischemic optic neuropathy)

Giant cell arteritis	
Symptoms	• Systemic: fever, fatigue, malaise, weight loss • Headache • Jaw claudication • Visual disturbances (eg, ischemic optic neuropathy) • **Polymyalgia rheumatica**
Diagnosis	• Elevated **erythrocyte sedimentation rate** & C-reactive protein • Temporal artery biopsy: intimal thickening, elastic lamina fragmentation, multinucleated giant cells
Treatment	• **Glucocorticoids**

This patient has acute, painless vision loss and unilateral headaches. This presentation is most consistent with **anterior ischemic optic neuropathy** (AION) due to **giant cell arteritis (GCA)**, also termed temporal arteritis. GCA occurs almost exclusively in patients **age >50** and is characterized by granulomatous inflammation of the media with fragmentation of the internal elastic lamina, primarily in the arteries of the head and neck. It is often associated with **polymyalgia rheumatica** (PMR), which presents with achy pain in the proximal skeletal muscles (eg, shoulders, hips).

Ocular manifestations are common in GCA and can lead to irreversible vision loss. AION is due to involvement of the ciliary arteries and causes a painless, rapidly progressive decrease in visual acuity. GCA can also cause visual symptoms due to central retinal artery occlusion, extraocular palsies, and infarcts of the visual cortex. Transient monocular vision loss (amaurosis fugax) may also be seen.

Treatment for GCA and PMR includes **systemic glucocorticoids** (eg, prednisone, methylprednisolone). However, for patients with suspected GCA, treatment should be started prior to diagnostic testing (eg, erythrocyte sedimentation rate, temporal artery biopsy) because of the risk of blindness if treatment is delayed.

(Choice A) Acetazolamide is a carbonic anhydrase inhibitor/diuretic used for treating idiopathic intracranial hypertension (ie, chronic headache and vision loss; occurs mainly in young, obese women) and angle-closure glaucoma (ie, eye pain, redness, middilated pupil, and cloudy cornea).

Treatment	• Glucocorticoids

This patient has acute, painless vision loss and unilateral headaches. This presentation is most consistent with **anterior ischemic optic neuropathy** (AION) due to **giant cell arteritis (GCA)**, also termed temporal arteritis. GCA occurs almost exclusively in patients **age >50** and is characterized by granulomatous inflammation of the media with fragmentation of the internal elastic lamina, primarily in the arteries of the head and neck. It is often associated with **polymyalgia rheumatica** (PMR), which presents with achy pain in the proximal skeletal muscles (eg, shoulders, hips).

Ocular manifestations are common in GCA and can lead to irreversible vision loss. AION is due to involvement of the ciliary arteries and causes a painless, rapidly progressive decrease in visual acuity. GCA can also cause visual symptoms due to central retinal artery occlusion, extraocular palsies, and infarcts of the visual cortex. Transient monocular vision loss (amaurosis fugax) may also be seen.

Treatment for GCA and PMR includes **systemic glucocorticoids** (eg, prednisone, methylprednisolone). However, for patients with suspected GCA, treatment should be started prior to diagnostic testing (eg, erythrocyte sedimentation rate, temporal artery biopsy) because of the risk of blindness if treatment is delayed.

(Choice A) Acetazolamide is a carbonic anhydrase inhibitor/diuretic used for treating idiopathic intracranial hypertension (ie, chronic headache and vision loss; occurs mainly in young, obese women) and angle-closure glaucoma (ie, eye pain, redness, middilated pupil, and cloudy cornea). Neither condition is associated with proximal muscle pain.

(Choice B) Antiplatelet agents (eg, aspirin, clopidogrel) are indicated for patients with amaurosis fugax (eg, transient vision loss) due to carotid atherosclerosis. However, this patient's unilateral headaches and proximal muscle pain makes GCA a more likely diagnosis.

(Choice C) Ganciclovir is used to treat cytomegalovirus retinitis, which presents with blurred vision, floaters, and photopsia (sensation of flashing lights). It occurs primarily in patients with significant immune suppression (eg, advanced AIDS).

(Choice E) Sumatriptan is used for the treatment of migraine, which can cause a variety of ocular symptoms. However, new-onset migraines are uncommon in older individuals, and this patient's other symptoms are more consistent with GCA and PMR.

Educational objective:
Ocular manifestations in giant cell arteritis (temporal arteritis) can lead to rapid, severe, and irreversible vision loss. Involvement of the ciliary arteries in GCA leads to anterior ischemic optic neuropathy, which presents with a painless, rapidly progressive decrease in visual acuity. Treatment includes systemic glucocorticoids (eg, prednisone, methylprednisolone).

palsies, and infarcts of the visual cortex. Transient monocular vision loss (amaurosis fugax) may also be seen.

Treatment for GCA and PMR includes **systemic glucocorticoids** (eg, prednisone, methylprednisolone). However, for patients with suspected GCA, treatment should be started prior to diagnostic testing (eg, erythrocyte sedimentation rate, temporal artery biopsy) because of the risk of blindness if treatment is delayed.

(Choice A) Acetazolamide is a carbonic anhydrase inhibitor/diuretic used for treating idiopathic intracranial hypertension (ie, chronic headache and vision loss; occurs mainly in young, obese women) and angle-closure glaucoma (ie, eye pain, redness, middilated pupil, and cloudy cornea). Neither condition is associated with proximal muscle pain.

(Choice B) Antiplatelet agents (eg, aspirin, clopidogrel) are indicated for patients with amaurosis fugax (eg, transient vision loss) due to carotid atherosclerosis. However, this patient's unilateral headaches and proximal muscle pain makes GCA a more likely diagnosis.

(Choice C) Ganciclovir is used to treat cytomegalovirus retinitis, which presents with blurred vision, floaters, and photopsia (sensation of flashing lights). It occurs primarily in patients with significant immune suppression (eg, advanced AIDS).

(Choice E) Sumatriptan is used for the treatment of migraine, which can cause a variety of ocular symptoms. However, new-onset migraines are uncommon in older individuals, and this patient's other symptoms are more consistent with GCA and PMR.

Educational objective:
Ocular manifestations in giant cell arteritis (temporal arteritis) can lead to rapid, severe, and irreversible vision loss. Involvement of the ciliary arteries in GCA leads to anterior ischemic optic neuropathy, which presents with a painless, rapidly progressive decrease in visual acuity. Treatment includes systemic glucocorticoids (eg, prednisone, methylprednisolone).

References

- Giant cell arteritis: ophthalmic manifestations of a systemic disease.

Pharmacology	Rheumatology/Orthopedics & Sports	Giant cell arteritis
Subject	System	Topic

Copyright © UWorld. All rights reserved.

A 55-year-old woman comes for evaluation of persistent morning stiffness. She was diagnosed with rheumatoid arthritis 4 months ago and was prescribed methotrexate. The patient currently takes the maximum tolerated dose, along with folic acid and as-needed naproxen. Vital signs are normal. On examination, swelling, tenderness, and pain on range of motion are found at the metacarpophalangeal and proximal interphalangeal joints and wrists bilaterally. Treatment with etanercept is considered. Which of the following tests should be performed before beginning treatment with this agent?

A. Brain CT scan

B. Echocardiogram

C. Fecal occult blood test

D. Pulmonary function tests

E. Tuberculin skin test

F. Visual examination

Submit

A 55-year-old woman comes for evaluation of persistent morning stiffness. She was diagnosed with rheumatoid arthritis 4 months ago and was prescribed methotrexate. The patient currently takes the maximum tolerated dose, along with folic acid and as-needed naproxen. Vital signs are normal. On examination, swelling, tenderness, and pain on range of motion are found at the metacarpophalangeal and proximal interphalangeal joints and wrists bilaterally. Treatment with etanercept is considered. Which of the following tests should be performed before beginning treatment with this agent?

- A. Brain CT scan (0%)
- B. Echocardiogram (3%)
- C. Fecal occult blood test (2%)
- D. Pulmonary function tests (7%)
- ✓ E. Tuberculin skin test (83%)
- F. Visual examination (2%)

Omitted
Correct answer
E

83%
Answered correctly

02 secs
Time Spent

04/07/2020
Last Updated

Explanation

Tumor necrosis factor-alpha (TNF-α) inhibitors are large-molecule anti-inflammatory agents ("biologics") commonly used to treat moderate to severe rheumatoid arthritis, particularly in patients who have failed methotrexate therapy. Etanercept is a fusion protein with domains derived from the Fc portion of IgG1 and TNF receptor 2. It functions as a **decoy receptor** for TNF-α. Other TNF-α inhibitors are anti-TNF monoclonal antibodies (eg, infliximab, adalimumab).

Tumor necrosis factor-alpha (TNF-α) inhibitors are large-molecule anti-inflammatory agents ("biologics") commonly used to treat moderate to severe rheumatoid arthritis, particularly in patients who have failed methotrexate therapy. Etanercept is a fusion protein with domains derived from the Fc portion of IgG1 and TNF receptor 2. It functions as a **decoy receptor** for TNF-α. Other TNF-α inhibitors are anti-TNF monoclonal antibodies (eg, infliximab, adalimumab).

Inhibition of TNF-α leads to impaired cell-mediated immunity. In particular, TNF-α is necessary for effective sequestration of mycobacteria within granulomas. As a result, TNF-α inhibitors promote reactivation of latent tuberculosis and can increase the risk of disseminated disease. All patients being considered for TNF-α inhibitor therapy should have a baseline tuberculin skin test or interferon-gamma release assay to screen for latent tuberculosis. TNF-α inhibitors also increase susceptibility to other infectious agents, including fungi and atypical mycobacteria, and should not be used in any patient with an underlying infection.

(Choice A) CT is effective in diagnosing a variety of infections of the central nervous system, including disseminated tuberculosis. However, a baseline CT scan is not needed in rheumatoid arthritis in the absence of suspicious symptoms.

(Choice B) Baseline assessment of left ventricular function with echocardiogram or radionuclide ventriculography is recommended prior to treatment with anthracycline antineoplastic drugs (eg, doxorubicin).

(Choice C) Patients taking nonsteroidal anti-inflammatory drugs (NSAIDs) are at increased risk for peptic ulcer. Fecal occult blood testing should be performed in patients taking NSAIDs whenever there is a clinical suspicion of gastrointestinal bleeding.

(Choice D) Pulmonary function tests may be important in patients taking medications known to cause pulmonary fibrosis, such as amiodarone. Methotrexate can cause both lung and liver toxicity, and a baseline chest x-ray and liver function tests are recommended.

(Choice F) Irreversible retinal damage can occur with long-term use of hydroxychloroquine. Patients starting hydroxychloroquine should have baseline and regular follow-up ophthalmologic examinations.

Educational objective:
Tumor necrosis factor-alpha (TNF-α) inhibitors impair cell-mediated immunity. All patients beginning treatment with TNF-α inhibitors should be evaluated for latent tuberculosis.

References

granulomas. As a result, TNF-α inhibitors promote reactivation of latent tuberculosis and can increase the risk of disseminated disease. All patients being considered for TNF-α inhibitor therapy should have a baseline tuberculin skin test or interferon-gamma release assay to screen for latent tuberculosis. TNF-α inhibitors also increase susceptibility to other infectious agents, including fungi and atypical mycobacteria, and should not be used in any patient with an underlying infection.

(Choice A) CT is effective in diagnosing a variety of infections of the central nervous system, including disseminated tuberculosis. However, a baseline CT scan is not needed in rheumatoid arthritis in the absence of suspicious symptoms.

(Choice B) Baseline assessment of left ventricular function with echocardiogram or radionuclide ventriculography is recommended prior to treatment with anthracycline antineoplastic drugs (eg, doxorubicin).

(Choice C) Patients taking nonsteroidal anti-inflammatory drugs (NSAIDs) are at increased risk for peptic ulcer. Fecal occult blood testing should be performed in patients taking NSAIDs whenever there is a clinical suspicion of gastrointestinal bleeding.

(Choice D) Pulmonary function tests may be important in patients taking medications known to cause pulmonary fibrosis, such as amiodarone. Methotrexate can cause both lung and liver toxicity, and a baseline chest x-ray and liver function tests are recommended.

(Choice F) Irreversible retinal damage can occur with long-term use of hydroxychloroquine. Patients starting hydroxychloroquine should have baseline and regular follow-up ophthalmologic examinations.

Educational objective:
Tumor necrosis factor-alpha (TNF-α) inhibitors impair cell-mediated immunity. All patients beginning treatment with TNF-α inhibitors should be evaluated for latent tuberculosis.

References

- Latent infection and tuberculosis disease in rheumatoid arthritis patients.

Pharmacology	Rheumatology/Orthopedics & Sports	Biologic agents
Subject	System	Topic

Copyright © UWorld. All rights reserved.

A 61-year-old man comes to the office to follow up acute arthritis. He was seen at a nearby urgent care center 6 weeks ago for sudden-onset pain and swelling in the ankle. The patient was treated with an unknown analgesic with rapid relief of his pain. Since that time, his pain has resolved completely and he is now feeling well. Past medical history is notable for hypercholesterolemia, for which he takes atorvastatin. He also has a history of recurrent renal colic. On examination, his ankle appears normal with no redness, warmth, or swelling. Serum uric acid level is 9.8 mg/dL. Which of the following is the best agent for long-term management of this patient?

- A. Antibiotics
- B. Cyclooxygenase inhibitor
- C. Glucocorticoid
- D. Lipoxygenase antagonist
- E. Uricosuric agents
- F. Xanthine oxidase inhibitor

Submit

A 61-year-old man comes to the office to follow up acute arthritis. He was seen at a nearby urgent care center 6 weeks ago for sudden-onset pain and swelling in the ankle. The patient was treated with an unknown analgesic with rapid relief of his pain. Since that time, his pain has resolved completely and he is now feeling well. Past medical history is notable for hypercholesterolemia, for which he takes atorvastatin. He also has a history of recurrent renal colic. On examination, his ankle appears normal with no redness, warmth, or swelling. Serum uric acid level is 9.8 mg/dL. Which of the following is the best agent for long-term management of this patient?

- A. Antibiotics (0%)
- B. Cyclooxygenase inhibitor (5%)
- C. Glucocorticoid (1%)
- D. Lipoxygenase antagonist (0%)
- E. Uricosuric agents (6%)
- ✓ F. Xanthine oxidase inhibitor (85%)

Omitted
Correct answer
F

85%
Answered correctly

02 secs
Time Spent

03/31/2020
Last Updated

Explanation

This patient had an episode of acute **gouty arthritis** that has responded to acute therapy. The decision now needs to be made whether to initiate long term preventive therapy. Patients who have only occasional episodes of gout may not need prophylactic treatment. However, uric acid-lowering medications can be helpful in patients with frequent episodes of gouty arthritis, chronic joint destruction, uric acid renal stones, or tophi.

In addition to acute gout, this patient has had recurring episodes of likely uric acid stones and should be considered for **prophylactic therapy**.

This patient had an episode of acute **gouty arthritis** that has responded to acute therapy. The decision now needs to be made whether to initiate long term preventive therapy. Patients who have only occasional episodes of gout may not need prophylactic treatment. However, uric acid-lowering medications can be helpful in patients with frequent episodes of gouty arthritis, chronic joint destruction, uric acid renal stones, or tophi.

In addition to acute gout, this patient has had recurring episodes of likely uric acid stones and should be considered for **prophylactic therapy**. The preferred treatment to prevent recurrent attacks is **xanthine oxidase inhibitors** (eg, allopurinol, febuxostat), which decrease uric acid production. Prophylactic therapy is usually initiated during intercritical (between attacks) periods as acute changes in serum uric acid levels can worsen an acute attack.

(Choice A) Septic arthritis can cause an acute monoarthritis but would be unlikely to respond to analgesics.

(Choice B) Nonsteroidal antiinflammatory drugs (NSAIDs) act by inhibiting cyclooxygenase. NSAIDs are the first-line therapy for acute gouty arthritis and can prevent an acute flare while urate-lowering therapy is started. However, they are not normally used for long-term therapy due to risk of peptic ulcer.

(Choice C) Oral or intraarticular glucocorticoids can be used for acute gout in patients who cannot tolerate NSAIDs or colchicine. However, they have significant long-term side effects.

(Choice D) Lipoxygenase inhibitors (eg, zileuton) are oral anti-inflammatory medications used in the long-term management of asthma. They are not useful for treatment of gout.

(Choice E) Uricosuric agents (eg, probenecid) are second-line drugs for chronic management of gout. These drugs increase renal excretion of uric acid and are therefore contraindicated in patients with a history of renal stones.

Educational objective:
Chronic uric acid-lowering therapy is recommended for patients with gout who have frequent gouty attacks, uric acid kidney stones, tophi, or chronic joint destruction from gout. Xanthine oxidase inhibitors are the preferred treatment.

References

- Therapeutic approaches to chronic hyperuricemia and gout.

In addition to acute gout, this patient has had recurring episodes of likely uric acid stones and should be considered for **prophylactic therapy**. The preferred treatment to prevent recurrent attacks is **xanthine oxidase inhibitors** (eg, allopurinol, febuxostat), which decrease uric acid production. Prophylactic therapy is usually initiated during intercritical (between attacks) periods as acute changes in serum uric acid levels can worsen an acute attack.

(Choice A) Septic arthritis can cause an acute monoarthritis but would be unlikely to respond to analgesics.

(Choice B) Nonsteroidal antiinflammatory drugs (NSAIDs) act by inhibiting cyclooxygenase. NSAIDs are the first-line therapy for acute gouty arthritis and can prevent an acute flare while urate-lowering therapy is started. However, they are not normally used for long-term therapy due to risk of peptic ulcer.

(Choice C) Oral or intraarticular glucocorticoids can be used for acute gout in patients who cannot tolerate NSAIDs or colchicine. However, they have significant long-term side effects.

(Choice D) Lipoxygenase inhibitors (eg, zileuton) are oral anti-inflammatory medications used in the long-term management of asthma. They are not useful for treatment of gout.

(Choice E) Uricosuric agents (eg, probenecid) are second-line drugs for chronic management of gout. These drugs increase renal excretion of uric acid and are therefore contraindicated in patients with a history of renal stones.

Educational objective:
Chronic uric acid-lowering therapy is recommended for patients with gout who have frequent gouty attacks, uric acid kidney stones, tophi, or chronic joint destruction from gout. Xanthine oxidase inhibitors are the preferred treatment.

References

- Therapeutic approaches to chronic hyperuricemia and gout.

Pharmacology	Rheumatology/Orthopedics & Sports	Gout
Subject	System	Topic

Copyright © UWorld. All rights reserved.

A 36-year-old man is evaluated due to swelling and severe pain of the right foot. Medical history is significant for kidney transplant due to focal segmental glomerulosclerosis. The patient is diagnosed with gout and treated with prednisone. Six weeks later, the patient is seen at follow-up. He has no foot pain and the swelling has subsided. Serum uric acid level is 13.5 mg/dL and creatinine level is 0.9 mg/dL. Allopurinol is prescribed. Initiation of this drug would most likely increase the activity of which of the following medications?

A. Azathioprine
B. Ganciclovir
C. Prednisone
D. Tacrolimus
E. Trimethoprim

Submit

A 36-year-old man is evaluated due to swelling and severe pain of the right foot. Medical history is significant for kidney transplant due to focal segmental glomerulosclerosis. The patient is diagnosed with gout and treated with prednisone. Six weeks later, the patient is seen at follow-up. He has no foot pain and the swelling has subsided. Serum uric acid level is 13.5 mg/dL and creatinine level is 0.9 mg/dL. Allopurinol is prescribed. Initiation of this drug would most likely increase the activity of which of the following medications?

- ✓ A. Azathioprine (85%)
- B. Ganciclovir (2%)
- C. Prednisone (1%)
- D. Tacrolimus (4%)
- E. Trimethoprim (5%)

Omitted
Correct answer
A

85%
Answered correctly

03 secs
Time Spent

04/20/2020
Last Updated

Explanation

Purine salvage pathway & 6-mercaptopurine metabolism

IMP AMP GMP

P_i 5'-Nucleotidase P_i 5'-Nucleotidase P_i

Purine salvage pathway & 6-mercaptopurine metabolism

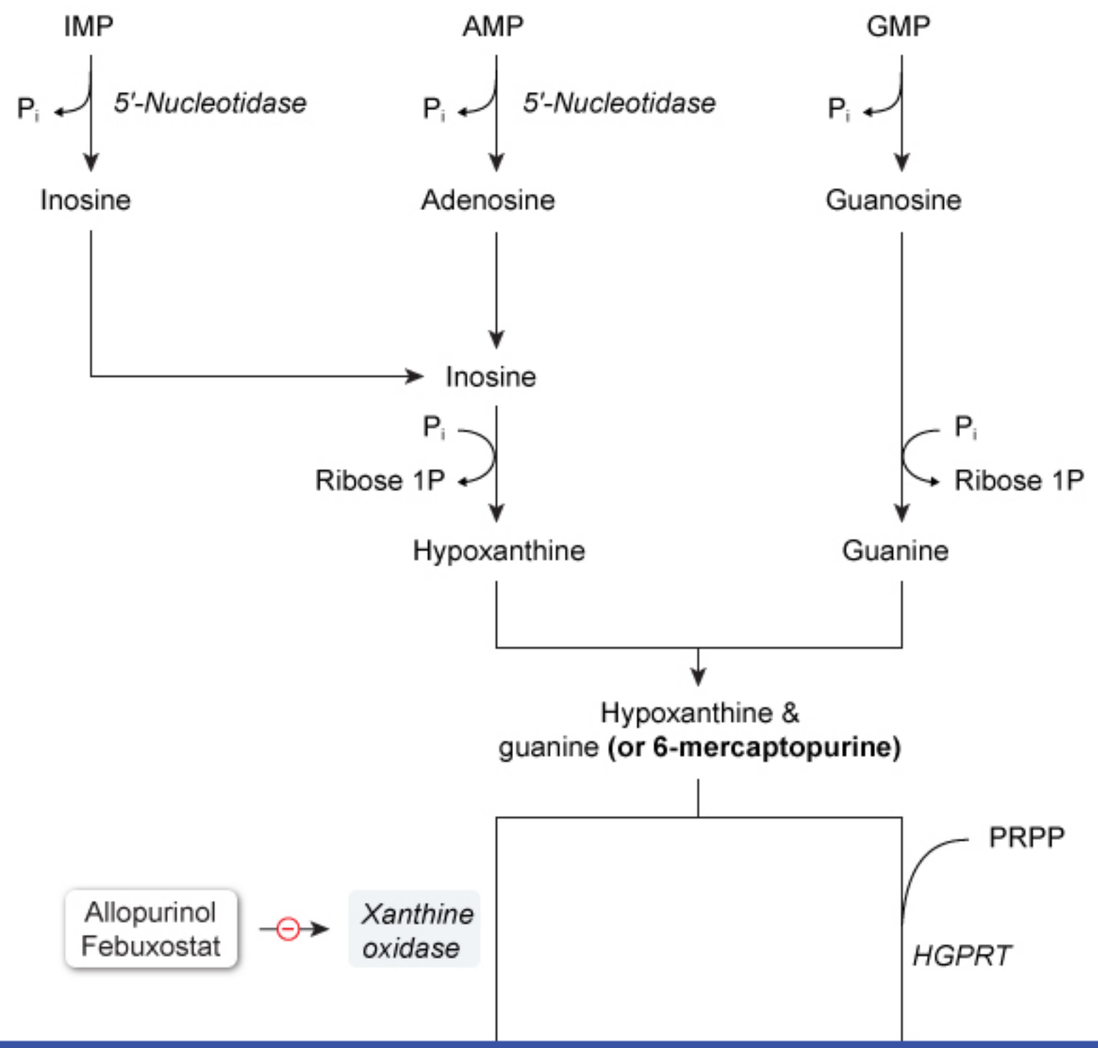

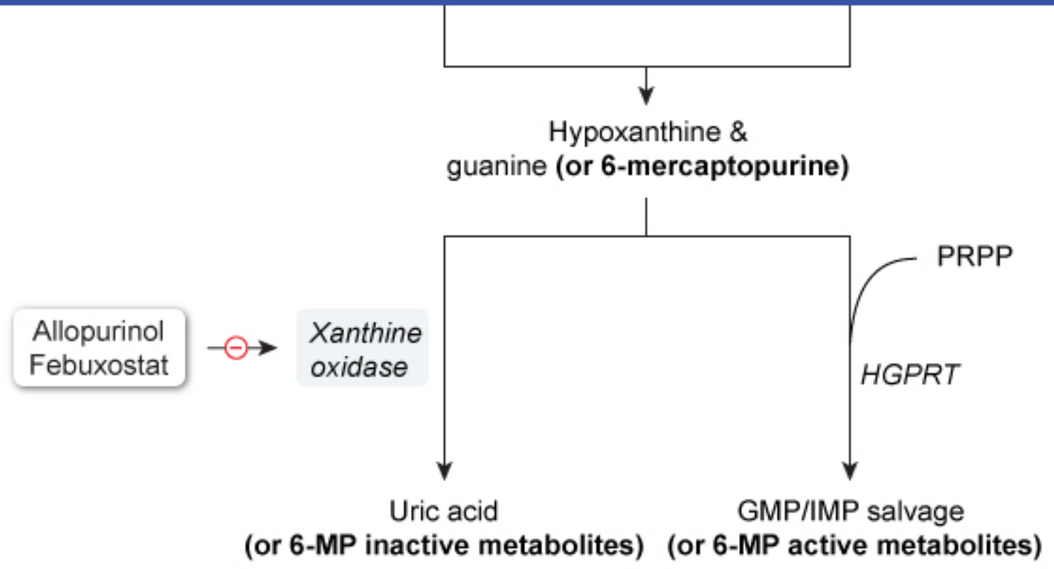

6-MP = 6-mercaptopurine; **GMP** = guanosine monophosphate; **HGPRT** = hypoxanthine-guanine phosphoribosyltransferase; **IMP** = inosine monophosphate; **Pi** = inorganic phosphate; **PRPP** = phosphoribosylpyrophosphate; **Ribose 1P** = ribose-1-phosphate.

In the purine degradation pathway, **purine bases** (ie, hypoxanthine, guanine) can follow 1 of 2 routes:

- Approximately 10% are **converted** by xanthine oxidase to **uric acid**, which is released into the bloodstream and excreted in the urine.
- The other 90% are recycled into purine nucleotides by hypoxanthine-guanine phosphoribosyltransferase (HGPRT) to be reused in the formation of DNA and RNA (ie, purine salvage).

Gout occurs due to elevated serum uric acid levels, leading to the formation of inflammation-inducing uric acid crystals within joints (eg, metatarsals). **Xanthine oxidase inhibitors** (eg, allopurinol, febuxostat) treat gout by **reducing uric acid** levels and in the process **shunt** additional **purine bases toward the salvage route**.

Azathioprine is an immunosuppression drug that is **metabolized** via the **purine degradation pathway**. Following ingestion, azathioprine is converted to 6-mercaptopurine (6-MP), which is a false purine base that, like hypoxanthine and guanine, can follow 1 of 2 routes. Some 6-MP is converted by xanthine oxidase (or thiopurine methyltransferase) into inactive metabolites that are excreted in the urine. The remainder is

formation of DNA and RNA (ie, purine salvage).

Gout occurs due to elevated serum uric acid levels, leading to the formation of inflammation-inducing uric acid crystals within joints (eg, metatarsals). **Xanthine oxidase inhibitors** (eg, allopurinol, febuxostat) treat gout by **reducing uric acid** levels and in the process **shunt** additional **purine bases toward the salvage route**.

Azathioprine is an immunosuppression drug that is **metabolized** via the **purine degradation pathway**. Following ingestion, azathioprine is converted to 6-mercaptopurine (6-MP), which is a false purine base that, like hypoxanthine and guanine, can follow 1 of 2 routes. Some 6-MP is converted by xanthine oxidase (or thiopurine methyltransferase) into inactive metabolites that are excreted in the urine. The remainder is converted by HGPRT into active metabolites (6-thioguanines), which act as false nucleotides that incorporate into DNA and RNA and inhibit hematopoietic cell proliferation. Therefore, when a **xanthine oxidase inhibitor is combined with azathioprine**, 6-MP is shunted toward **conversion into active metabolites**, leading to increased immunosuppression and risk of **cellular toxicity**.

(Choice B) Ganciclovir is similar in structure to guanosine and forms false purine nucleotides that disrupt DNA synthesis. It is relatively specific for viral DNA replication enzymes; it does not interact with allopurinol because it is not catabolized by xanthine oxidase.

(Choices C and D) Prednisone exerts a nonspecific immunosuppressive effect by inhibiting NF-kB to regulate the transcription of leukoproliferative cytokines. Tacrolimus is a calcineurin inhibitor that suppresses T cells by preventing IL-2 transcription. Neither drug targets the purine degradation pathway and therefore is not significantly influenced by xanthine oxidase inhibition.

(Choice E) Trimethoprim inhibits dihydrofolate reductase to disrupt folate metabolism and inhibit the production of pyrimidine nucleotides. It is not affected by the inhibition of xanthine oxidase in the purine degradation pathway.

Educational objective:
Azathioprine is an immunosuppression drug that is metabolized into active metabolites by HGPRT and, conversely, inactivated by xanthine oxidase. Coadministration with a xanthine oxidase inhibitor (eg, allopurinol, febuxostat) shunts azathioprine metabolism toward the production of active metabolites, resulting in increased immunosuppression and risk of cellular toxicity.

References

- Myelosuppression associated with azathioprine-allopurinol interaction after heart and lung transplantation.

Pharmacology Rheumatology/Orthopedics & Sports Azathioprine

formation of DNA and RNA (ie, purine salvage).

Exhibit Display

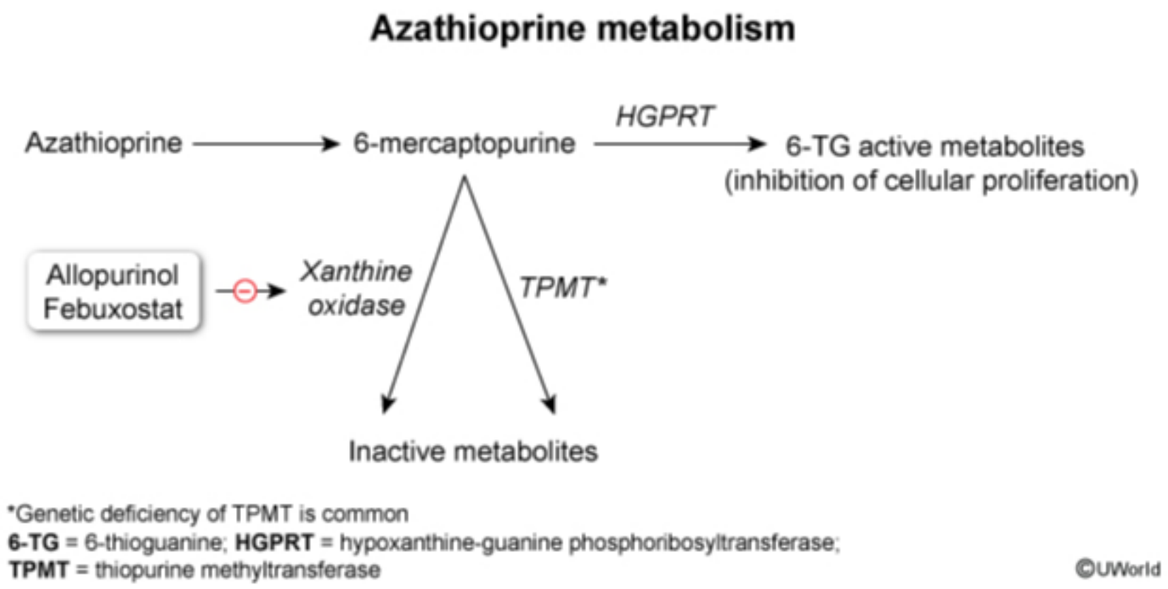

Zoom In | Zoom Out | Reset | Add To New Card | Existing Card

Pharmacology | Rheumatology/Orthopedics & Sports | Azathioprine

A 74-year-old woman comes to the emergency department due to left hip pain and inability to walk after a fall. She is being treated by her primary care provider for various medical conditions including hypertension, congestive heart failure, chronic atrial fibrillation, type 2 diabetes mellitus, trigeminal neuralgia, depression, and gastroesophageal reflux disease. On examination, the left leg is shorter than the right and externally rotated. She is not able to move the left hip. An imaging study confirms acute femoral neck fracture. Her bone density, measured by quantitative x-ray densitometry, is consistent with osteoporosis. Which of the following drugs, had it been used as part of the medical regimen, would have had a beneficial effect on calcium homeostasis and reduced this patient's fracture risk?

A. Carbamazepine
B. Diltiazem
C. Escitalopram
D. Furosemide
E. Hydrochlorothiazide
F. Lansoprazole
G. Metformin
H. Spironolactone

Submit

A 74-year-old woman comes to the emergency department due to left hip pain and inability to walk after a fall. She is being treated by her primary care provider for various medical conditions including hypertension, congestive heart failure, chronic atrial fibrillation, type 2 diabetes mellitus, trigeminal neuralgia, depression, and gastroesophageal reflux disease. On examination, the left leg is shorter than the right and externally rotated. She is not able to move the left hip. An imaging study confirms acute femoral neck fracture. Her bone density, measured by quantitative x-ray densitometry, is consistent with osteoporosis. Which of the following drugs, had it been used as part of the medical regimen, would have had a beneficial effect on calcium homeostasis and reduced this patient's fracture risk?

- A. Carbamazepine (0%)
- B. Diltiazem (2%)
- C. Escitalopram (2%)
- D. Furosemide (4%)
- ✓ E. Hydrochlorothiazide (81%)
- F. Lansoprazole (2%)
- G. Metformin (1%)
- H. Spironolactone (5%)

Omitted
Correct answer
E

81%
Answered correctly

02 secs
Time Spent

02/11/2020
Last Updated

Explanation

Effect of thiazide diuretics on distal tubular calcium reabsorption

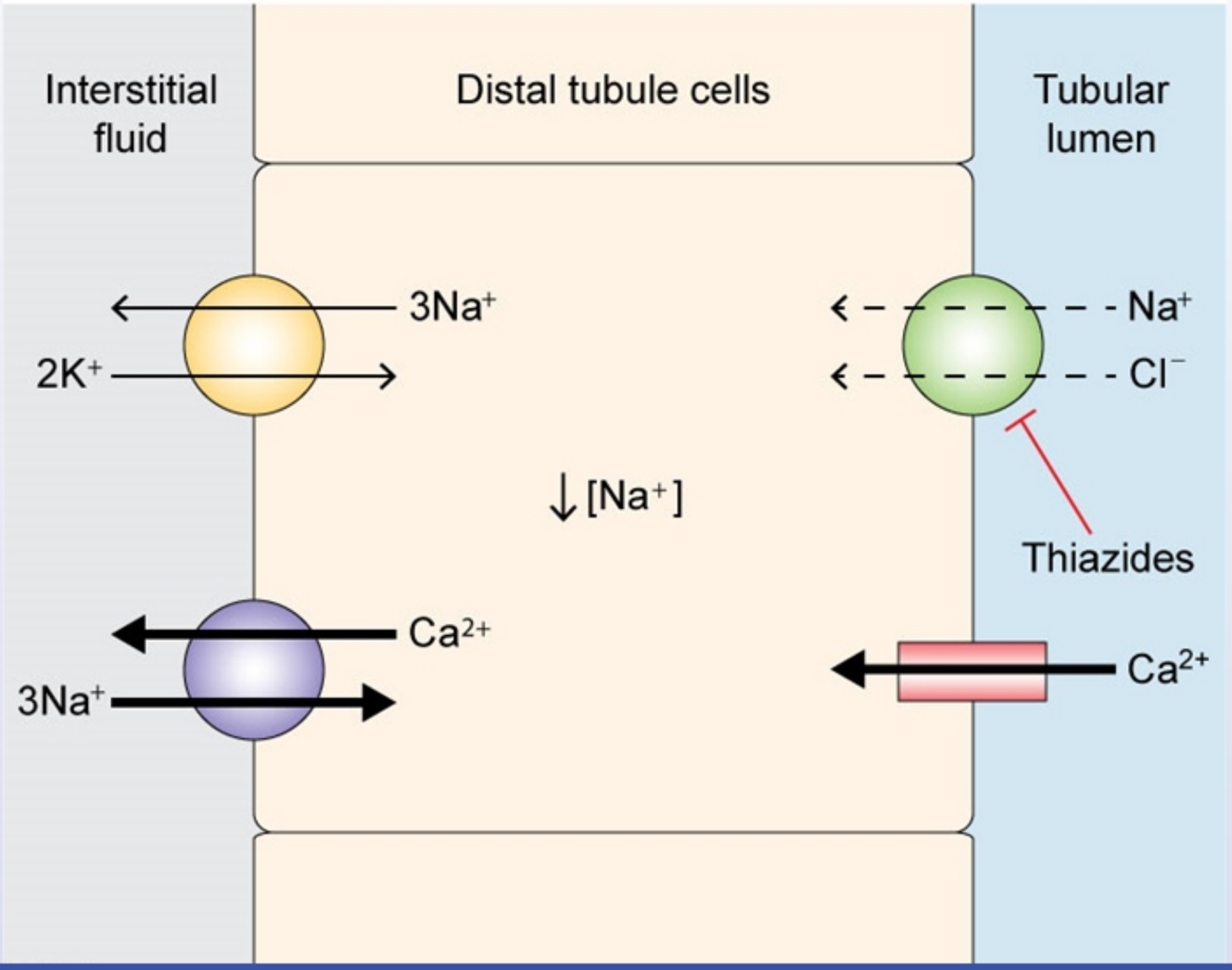

©UWorld

Thiazide diuretics (eg, hydrochlorothiazide, chlorthalidone) are indicated for treatment of patients with hypertension, including those who also have diabetes mellitus. Although thiazides can cause a small increase in blood glucose, this effect is often not clinically significant and substantially outweighed by their blood pressure-lowering benefits.

Thiazides inhibit the **Na-Cl cotransporter** in the distal convoluted tubule, leading to decreased sodium reabsorption. Thiazides also cause peripheral vasodilation, resulting in reduced peripheral vascular resistance. In addition, thiazide diuretics increase **calcium reabsorption** in the distal tubule. Studies have shown that use of thiazides is associated with higher bone mineral density and reduced fracture risk, and many experts recommend them for treatment of hypertension in patients who are at risk for osteoporosis. Increased calcium reabsorption also causes hypocalciuria, which may prevent recurrent renal stones in some patients.

(Choice A) Several antiepileptic drugs (eg, phenytoin, carbamazepine, phenobarbital) are associated with decreased bone mineral density and increased risk of osteoporosis.

(Choice B) Diltiazem is a calcium channel blocker that is indicated for treatment of hypertension. It is also used for rate control in patients with atrial fibrillation. It has no significant effect on serum calcium levels, bone density, or fracture risk.

(Choice C) Escitalopram is a selective serotonin reuptake inhibitor (SSRI) indicated for treatment of depression and generalized anxiety disorder. SSRIs are associated with a small decrease in bone density; their effect on fracture risk has not been well studied.

(Choice D) Furosemide is a loop diuretic used to treat congestive heart failure (CHF). It causes an increase in urinary calcium loss that may worsen osteoporosis.

(Choice F) Lansoprazole is a proton pump inhibitor (PPI) used to treat gastroesophageal reflux and peptic ulcer. PPIs inhibit the enzyme H-K-ATPase on gastric parietal cells and reduce gastric acid secretion. PPIs also decrease calcium and magnesium absorption, and long-term use is associated with an increased risk of osteoporosis.

(Choice G) Metformin suppresses hepatic gluconeogenesis and increases insulin sensitivity and peripheral glucose uptake. It has no significant effect on osteoporosis risk.

(Choice H) Spironolactone is an aldosterone inhibitor used to treat CHF. Spironolactone can cause hyperkalemia, but it does not have a significant effect on calcium homeostasis.

atrial fibrillation. It has no significant effect on serum calcium levels, bone density, or fracture risk.

(Choice C) Escitalopram is a selective serotonin reuptake inhibitor (SSRI) indicated for treatment of depression and generalized anxiety disorder. SSRIs are associated with a small decrease in bone density; their effect on fracture risk has not been well studied.

(Choice D) Furosemide is a loop diuretic used to treat congestive heart failure (CHF). It causes an increase in urinary calcium loss that may worsen osteoporosis.

(Choice F) Lansoprazole is a proton pump inhibitor (PPI) used to treat gastroesophageal reflux and peptic ulcer. PPIs inhibit the enzyme H-K-ATPase on gastric parietal cells and reduce gastric acid secretion. PPIs also decrease calcium and magnesium absorption, and long-term use is associated with an increased risk of osteoporosis.

(Choice G) Metformin suppresses hepatic gluconeogenesis and increases insulin sensitivity and peripheral glucose uptake. It has no significant effect on osteoporosis risk.

(Choice H) Spironolactone is an aldosterone inhibitor used to treat CHF. Spironolactone can cause hyperkalemia, but it does not have a significant effect on calcium homeostasis.

Educational objective:
Thiazide diuretics increase calcium absorption in the distal convoluted tubules within the nephron. Thiazides are associated with increased bone mineral density and are recommended for treatment of hypertension in patients at risk for osteoporosis. Loop diuretics increase urinary calcium loss.

References

- 7B.10: Thiazide diuretics and fracture-risk among hypertensive patients. Results from the Swedish primary care cardiovascular database (SPCCD).

Pharmacology	Rheumatology/Orthopedics & Sports	Thiazides
Subject	System	Topic

Copyright © UWorld. All rights reserved.

A 56-year-old man comes to the urgent care center with severe knee pain. He was feeling well until he awoke this morning with acute pain, redness, and swelling in the knee. The patient does not smoke but did drink heavily at a wedding reception the night before. Past medical history is notable for recent peptic ulcer disease. He is treated with oral colchicine and experiences significant relief of symptoms within 12 hours. The drug used in this patient most likely affects which of the steps shown in the diagram below?

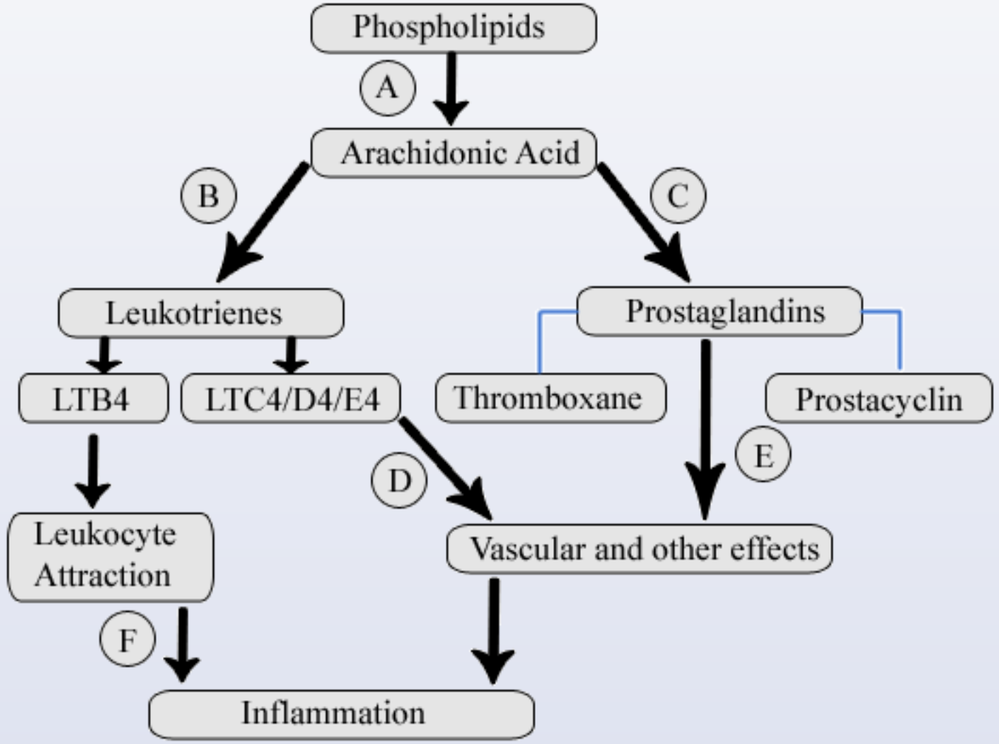

A. A
B. B
C. C

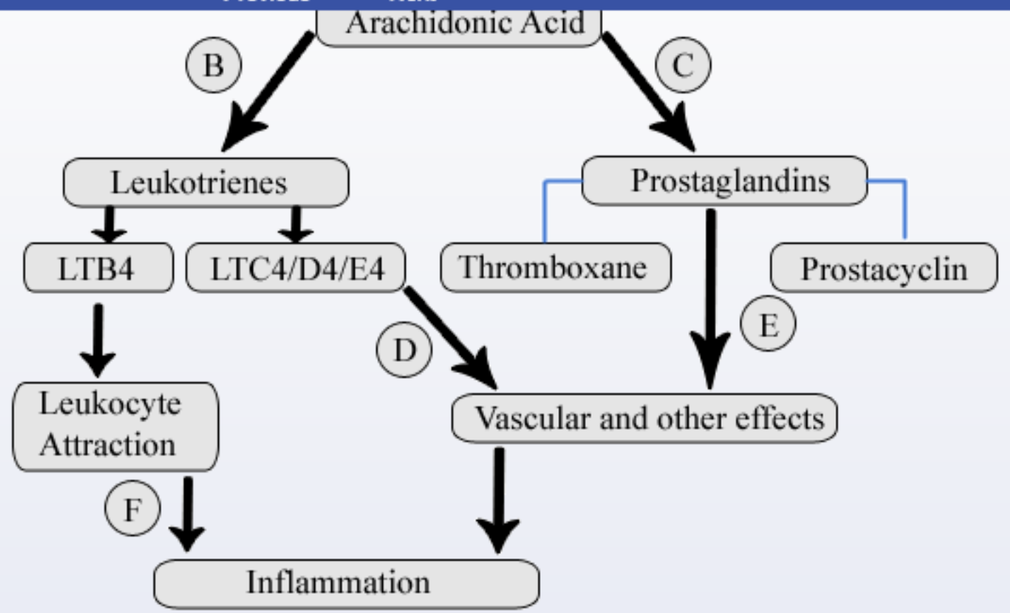

- A. A (6%)
- B. B (5%)
- C. C (9%)
- D. D (2%)
- E. E (4%)
- ✓ F. F (70%)

Omitted
Correct answer

70%
Answered correctly

03 secs
Time Spent

01/19/2020
Last Updated

This patient with acute atraumatic monoarticular arthritis involving the knee has typical symptoms of **gout**. The usual first-line treatment of acute gouty arthritis is nonsteroidal anti-inflammatory drugs (NSAIDs) (eg, indomethacin), but these are relatively contraindicated in patients with a history of peptic ulcer. **Colchicine** can also be used to treat acute gouty arthritis and results in resolution of symptoms in most patients.

Colchicine works primarily by inhibiting **microtubular polymerization**. It binds to the tubulin protein that helps form microtubules, preventing their aggregation. This in turn disrupts cytoskeletal-dependent functions such as **chemotaxis, phagocytosis, and degranulation**. Colchicine also reduces the formation of leukotriene B_4. It does not have any effect on the metabolism or urinary excretion of uric acid. Important adverse effects of colchicine are nausea, abdominal pain, and diarrhea. Colchicine should not be used in elderly patients or those with severe renal dysfunction.

(Choices A and E) Glucocorticoids inhibit the enzyme phospholipase A_2, which converts membrane phospholipids to arachidonic acid. This in turn decreases the formation of inflammatory prostaglandins and leukotrienes. Glucocorticoids can be given systemically or by intra-articular injection for treatment of gout in patients who cannot take NSAIDs or colchicine.

(Choices B and D) The leukotriene pathways can be blocked by inhibiting the 5-lipoxygenase pathway or by blocking the leukotriene receptors. Zileuton is a specific inhibitor of the enzyme 5-lipoxygenase and inhibits leukotriene formation (LTB_4, LTC_4, LTD_4, and LTE_4). Montelukast inhibits LTD_4 receptors. Leukotriene modifiers are used in the treatment of asthma and allergic rhinitis but have no role in the treatment of gout.

(Choice C) Cyclooxygenase (COX) catalyzes the conversion of arachidonic acid to prostanoids. It exists in 2 isoforms, COX-1 and COX-2. COX-2 is an inducible enzyme that is upregulated in inflammatory cells to increase synthesis of pro-inflammatory arachidonic acid metabolites. Standard NSAIDs (eg, indomethacin, ibuprofen) inhibit both COX-1 and COX-2, while selective COX-2 inhibitors (eg, celecoxib) inhibit only COX-2.

Educational objective:
Colchicine is used for treatment of acute gouty arthritis in patients who cannot take nonsteroidal anti-inflammatory drugs. It inhibits leukocyte migration and phagocytosis by blocking tubulin polymerization. Significant side effects of colchicine include nausea and diarrhea.

References

- Mechanism of action of colchicine in the treatment of gout.

Pharmacology Rheumatology/Orthopedics & Sports Gout

Exhibit Display

Zoom In
Zoom Out
Reset
Add To New Card | Existing Card

Pharmacology
Rheumatology/Orthopedics & Sports
Gout

1
2
3
4
5
6
7
8
9
10
11
12
13
14
15
16
17
18
19
20

Exhibit Display

Arachidonic acid metabolic pathways

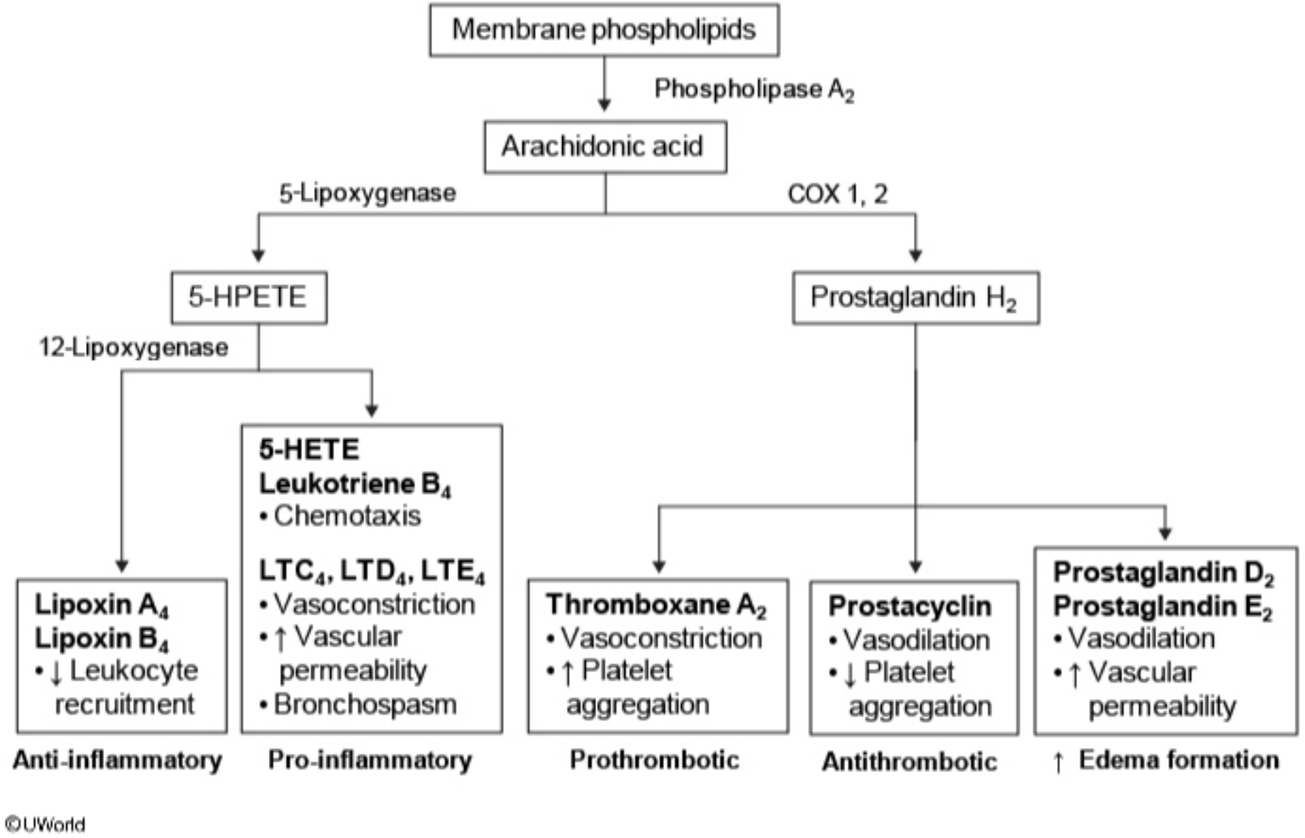

Zoom In | Zoom Out | Reset | Add To New Card | Existing Card

Pharmacology | Rheumatology/Orthopedics & Sports | Gout

A 45-year-old man comes to the emergency department due to 2 days of left knee swelling and pain. The patient has no significant past medical history apart from an episode of facial palsy 3 months ago. Six months ago, he went on a hiking trip to New Hampshire but has no other travel history. The patient is in a long-standing monogamous relationship with his wife and has had no other sexual partners. Temperature is 37.1 C (98.8 F). Examination shows left knee joint swelling with no surrounding erythema. The remainder of the musculoskeletal examination is unremarkable. There is no heart murmur. Which of the following might have prevented this patient's knee condition?

A. Allopurinol
B. Ceftriaxone
C. Lamivudine
D. Live attenuated vaccine
E. Mefloquine
F. Metronidazole

Submit

A 45-year-old man comes to the emergency department due to 2 days of left knee swelling and pain. The patient has no significant past medical history apart from an episode of facial palsy 3 months ago. Six months ago, he went on a hiking trip to New Hampshire but has no other travel history. The patient is in a long-standing monogamous relationship with his wife and has had no other sexual partners. Temperature is 37.1 C (98.8 F). Examination shows left knee joint swelling with no surrounding erythema. The remainder of the musculoskeletal examination is unremarkable. There is no heart murmur. Which of the following might have prevented this patient's knee condition?

- A. Allopurinol (10%)
- ✓ B. Ceftriaxone (65%)
- C. Lamivudine (2%)
- D. Live attenuated vaccine (6%)
- E. Mefloquine (6%)
- F. Metronidazole (7%)

Omitted
Correct answer
B

65%
Answered correctly

02 secs
Time Spent

04/22/2020
Last Updated

Explanation

This patient has symptoms consistent with long-standing **Lyme disease**. Lyme disease is caused by the spirochete ***Borrelia burgdorferi***, which is transmitted by the bite of an *Ixodes* tick. Lyme disease is endemic in the northeastern United States and northern Europe. Like syphilis, another spirochetal infection, Lyme disease progresses through a predictable series of phases:

1. Early localized phase: Days to weeks following exposure, patients experience flu-like symptoms and the characteristic cutaneous eruption

This patient has symptoms consistent with long-standing **Lyme disease**. Lyme disease is caused by the spirochete ***Borrelia burgdorferi***, which is transmitted by the bite of an *Ixodes* tick. Lyme disease is endemic in the northeastern United States and northern Europe. Like syphilis, another spirochetal infection, Lyme disease progresses through a predictable series of phases:

1. Early localized phase: Days to weeks following exposure, patients experience flu-like symptoms and the characteristic cutaneous eruption, erythema chronicum migrans (ECM).
2. Early disseminated phase: Weeks or months later, there may be central nervous system (eg, **facial palsy**) and/or cardiac involvement (eg, atrioventricular **nodal block**).
3. Late Lyme disease: This phase, which occurs months to years post-exposure, is rare given the frequency with which patients receive antibiotics for other indications. Patients may experience **asymmetric arthritis** (most often involving a **single knee joint**, as in this patient) and/or subacute **encephalopathy** with decreased memory, somnolence, and mood changes.

Lyme disease is easily treated with **doxycycline** or penicillin-type antibiotics (eg, ceftriaxone). This patient does not appear to have noted ECM, for which he would likely have received doxycycline. However, treatment with **ceftriaxone** when he developed the facial palsy (a possible manifestation of early disseminated Lyme disease) would have prevented progression to late Lyme disease.

(Choice A) Allopurinol competitively inhibits xanthine oxidase, suppressing uric acid synthesis. This drug is used to treat gout and prevent uric acid kidney stones and tumor lysis syndrome.

(Choice C) Lamivudine is a nucleoside reverse transcriptase inhibitor used for HIV treatment.

(Choice D) A *Borrelia burgdorferi* vaccine, now discontinued due to low sales, contains a recombinant outer surface protein from these bacteria, not live organisms.

(Choice E) Mefloquine is an antimalarial drug used in prevention and treatment of *Plasmodium falciparum* infections, among others.

(Choice F) Metronidazole is effective against anaerobic bacteria (eg, *Clostridium difficile, Bacteroides*) and parasites (eg, *Entamoeba histolytica, Giardia lamblia, Trichomonas vaginalis*).

Educational objective:
Early Lyme disease causes flu-like symptoms and erythema chronicum migrans. The second stage of Lyme disease may involve atrioventricular

atrioventricular **nodal block**).

3. Late Lyme disease: This phase, which occurs months to years post-exposure, is rare given the frequency with which patients receive antibiotics for other indications. Patients may experience **asymmetric arthritis** (most often involving a **single knee joint**, as in this patient) and/or subacute **encephalopathy** with decreased memory, somnolence, and mood changes.

Lyme disease is easily treated with **doxycycline** or penicillin-type antibiotics (eg, ceftriaxone). This patient does not appear to have noted ECM, for which he would likely have received doxycycline. However, treatment with **ceftriaxone** when he developed the facial palsy (a possible manifestation of early disseminated Lyme disease) would have prevented progression to late Lyme disease.

(Choice A) Allopurinol competitively inhibits xanthine oxidase, suppressing uric acid synthesis. This drug is used to treat gout and prevent uric acid kidney stones and tumor lysis syndrome.

(Choice C) Lamivudine is a nucleoside reverse transcriptase inhibitor used for HIV treatment.

(Choice D) A *Borrelia burgdorferi* vaccine, now discontinued due to low sales, contains a recombinant outer surface protein from these bacteria, not live organisms.

(Choice E) Mefloquine is an antimalarial drug used in prevention and treatment of *Plasmodium falciparum* infections, among others.

(Choice F) Metronidazole is effective against anaerobic bacteria (eg, *Clostridium difficile, Bacteroides*) and parasites (eg, *Entamoeba histolytica, Giardia lamblia, Trichomonas vaginalis*).

Educational objective:
Early Lyme disease causes flu-like symptoms and erythema chronicum migrans. The second stage of Lyme disease may involve atrioventricular block and facial palsy. Late Lyme disease can cause chronic asymmetric large joint arthritis and encephalopathy. Lyme disease is easily treated with doxycycline or penicillin-type antibiotics (eg, ceftriaxone).

Pharmacology	Rheumatology/Orthopedics & Sports	Lyme disease
Subject	System	Topic

Copyright © UWorld. All rights reserved.

Exhibit Display

Zoom In
Zoom Out
Reset
Add To New Card | Existing Card

not live organisms.

A 28-year-old woman comes to the clinic for follow-up after recent hospitalization due to autoimmune hepatitis. High-dose glucocorticoids improved the hepatitis, and on discharge, the patient continued prednisone therapy. Today, she feels well and has no other medical concerns. Physical examination shows no abdominal tenderness or jaundice. Prednisone is tapered and azathioprine is prescribed for continued management of autoimmune hepatitis. Which of the following should be periodically monitored while the patient is taking this new medication?

A. Complete blood count

B. Hemoglobin A1c

C. Lipid panel

D. Pulmonary function testing

E. Vitamin B_{12} level

Submit

A 28-year-old woman comes to the clinic for follow-up after recent hospitalization due to autoimmune hepatitis. High-dose glucocorticoids improved the hepatitis, and on discharge, the patient continued prednisone therapy. Today, she feels well and has no other medical concerns. Physical examination shows no abdominal tenderness or jaundice. Prednisone is tapered and azathioprine is prescribed for continued management of autoimmune hepatitis. Which of the following should be periodically monitored while the patient is taking this new medication?

- ✓ A. Complete blood count (85%)
- B. Hemoglobin A1c (2%)
- C. Lipid panel (5%)
- D. Pulmonary function testing (2%)
- E. Vitamin B_{12} level (4%)

Omitted
Correct answer
A

85%
Answered correctly

02 secs
Time Spent

04/22/2020
Last Updated

Explanation

Immunosuppressant inhibition of purine synthesis

De novo pathway

Ribose 5-phosphate

Immunosuppressant inhibition of purine synthesis

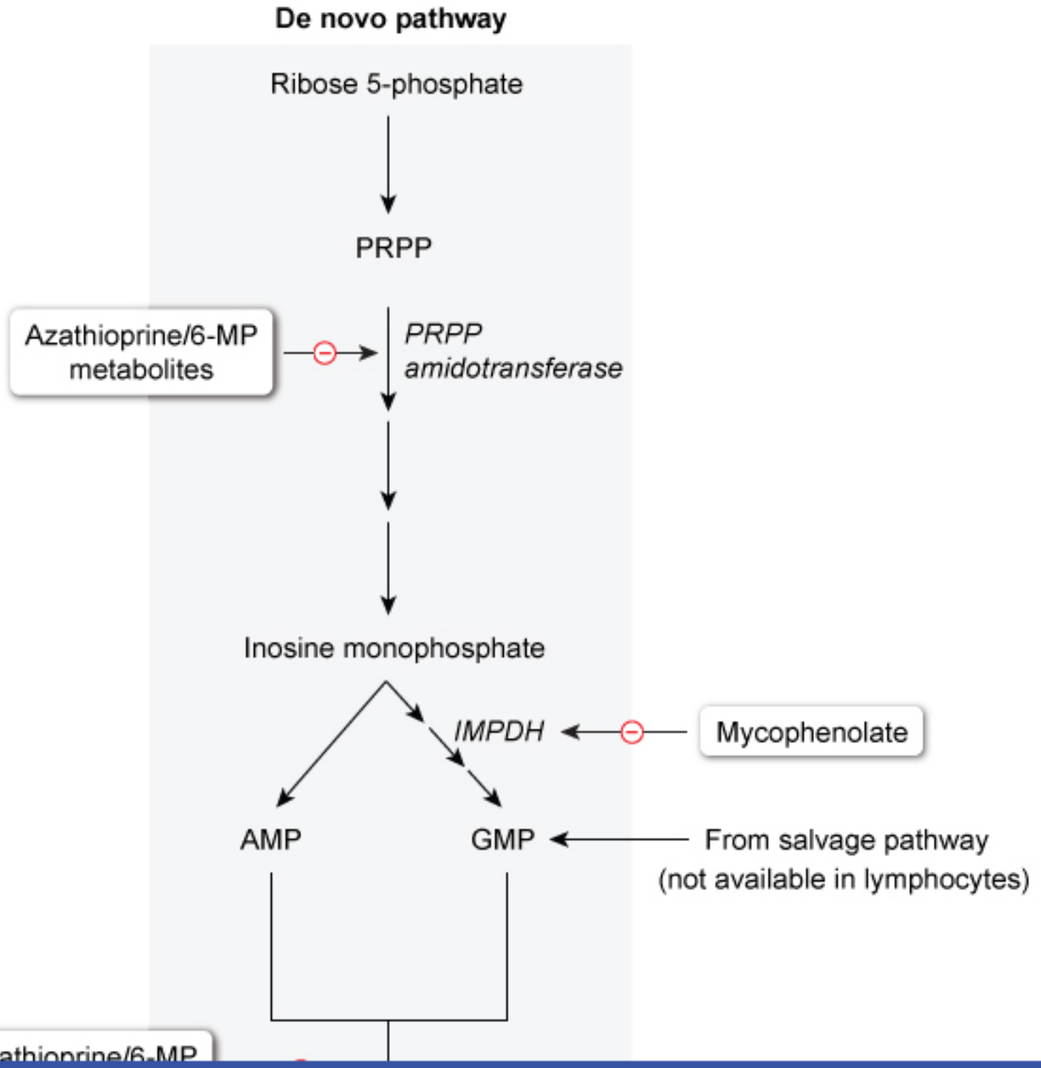

1
2
3
4
5
6
7
8
9
10
11
12
13
14
15
16
17
18
19
20

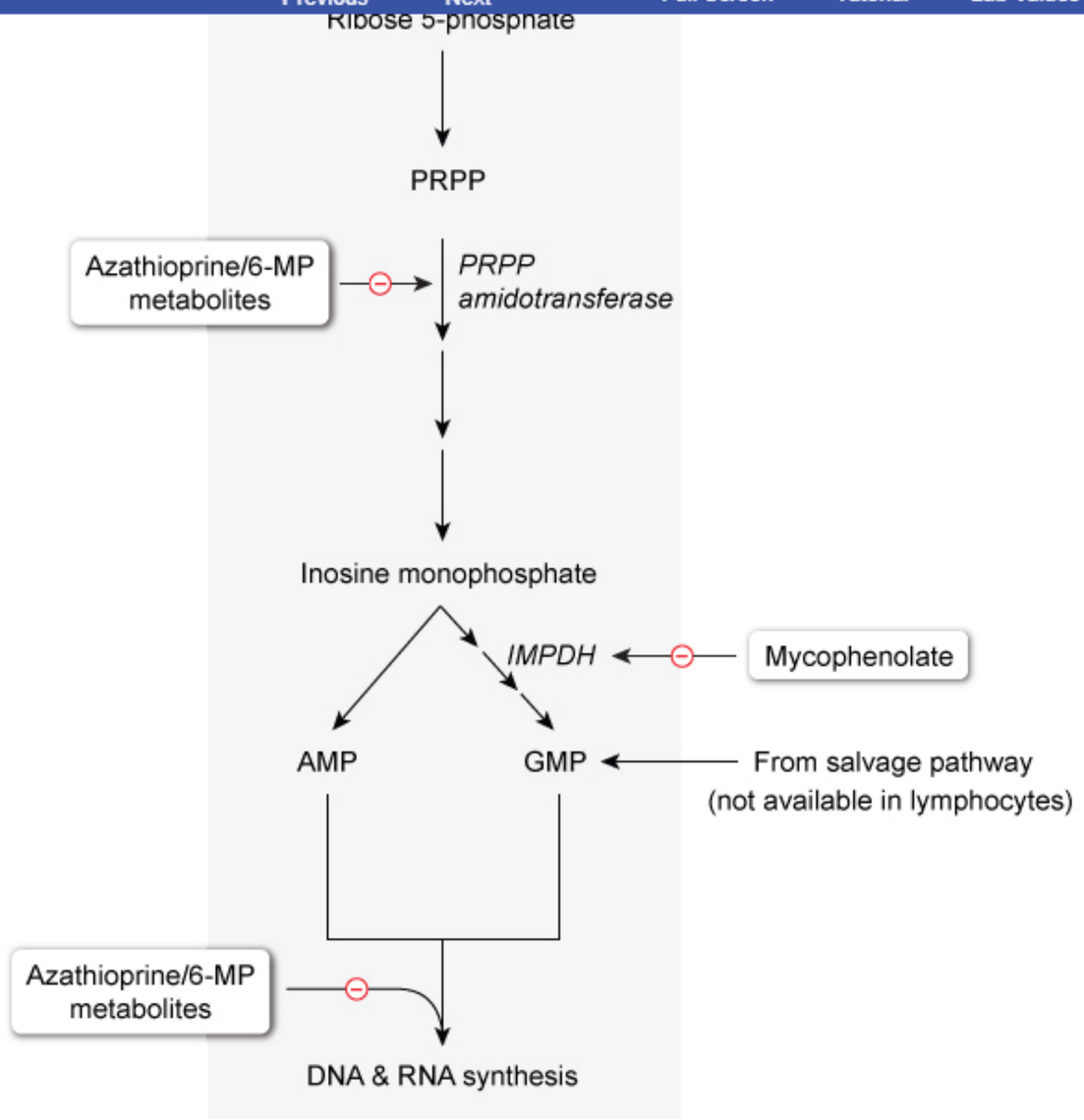

6-MP = 6-mercaptopurine; **AMP** = adenosine monophosphate, **GMP** = guanosine monophosphate; **IMPDH** = inosine monophosphate dehydrogenase; **PRPP** = phosphoribosyl pyrophosphate.

©UWorld

Azathioprine is an **immunosuppressant** used in the prevention of organ transplant rejection and the treatment of autoimmune diseases, including rheumatoid arthritis, inflammatory bowel disease, and autoimmune hepatitis. It functions via inhibition of purine synthesis pathways. Following ingestion, azathioprine is converted to 6-mercaptopurine, which is then converted to **6-thioguanine metabolites**; these metabolites are pharmacologically active and mediate both the therapeutic and adverse effects of azathioprine.

The 6-thioguanine metabolites reduce cellular proliferation via 2 methods of purine synthesis inhibition:

- The metabolites **inhibit** phosphoribosylpyrophosphate **(PRPP) amidotransferase**, an enzyme that catalyzes an early step in **de novo purine synthesis**.
- The metabolites act as **false nucleotides**, incorporating into actively replicating DNA and RNA and rendering the growing nucleic acid strand nonfunctional.

These effects are exerted preferentially on rapidly dividing cells (eg, activated lymphocytes in the setting of organ transplant or autoimmune disease) but are otherwise nonspecific and disrupt other hematologic cell lines, including neutrophils, erythrocytes, and platelets. Therefore, **pancytopenia** (ie, leukopenia, anemia, and thrombocytopenia) is a common **adverse effect** that must be **monitored** with periodic **complete blood count** testing.

(Choices B and C) Unlike glucocorticoids, azathioprine has no adverse effects on glucose or lipid metabolism, an advantage of this medication over chronic glucocorticoid therapy.

(Choice D) Azathioprine has no known effect on lung function. The chemotherapeutic agent bleomycin may cause pulmonary fibrosis and therefore requires periodic monitoring of pulmonary function.

(Choice E) The anemia caused by azathioprine and other antimetabolite drugs (eg, methotrexate) is typically macrocytic (due to impaired DNA synthesis), but this macrocytic effect is independent of vitamin B_{12} levels. Proton pump inhibitors and histamine 2 blockers can disrupt absorption of vitamin B_{12} and may cause or contribute to its deficiency.

Educational objective:
Azathioprine is an immunosuppressant that functions via inhibition of purine synthesis by its pharmacologically active 6-thioguanine metabolites. In addition to the desired effect of reduced lymphocyte proliferation, the proliferation of other hematologic cell lines (eg, neutrophils, erythrocytes,

Exhibit Display

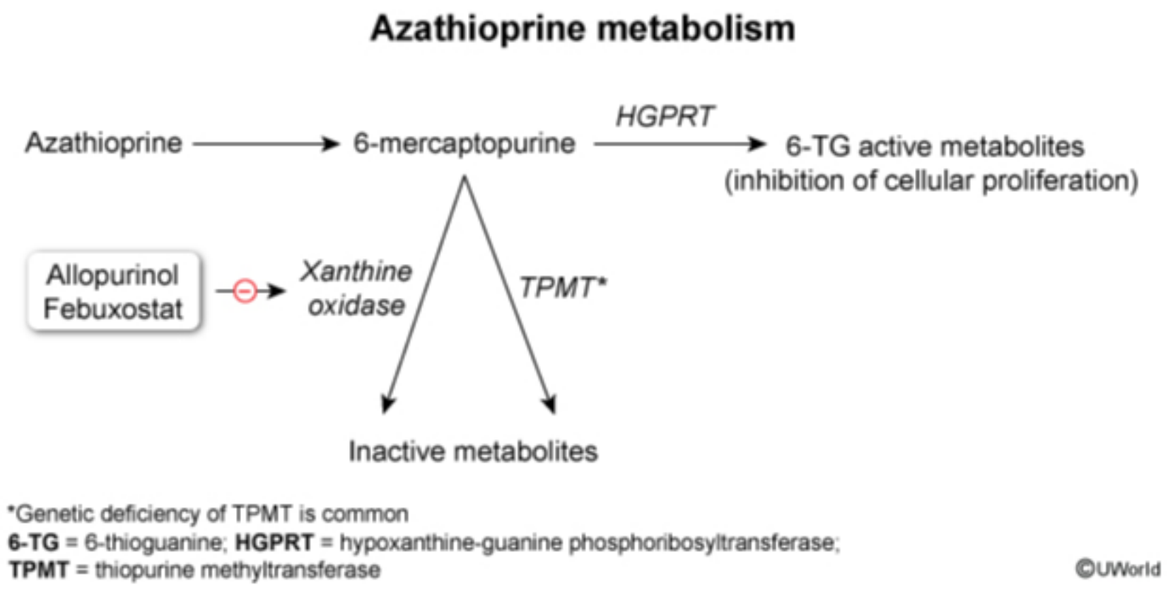

Zoom In Zoom Out Reset Add To Flash Card

In addition to the desired effect of reduced lymphocyte proliferation, the proliferation of other hematologic cell lines (eg, neutrophils, erythrocytes,

- The metabolites act as **false nucleotides**, incorporating into actively replicating DNA and RNA and rendering the growing nucleic acid strand nonfunctional.

These effects are exerted preferentially on rapidly dividing cells (eg, activated lymphocytes in the setting of organ transplant or autoimmune disease) but are otherwise nonspecific and disrupt other hematologic cell lines, including neutrophils, erythrocytes, and platelets. Therefore, **pancytopenia** (ie, leukopenia, anemia, and thrombocytopenia) is a common **adverse effect** that must be **monitored** with periodic **complete blood count** testing.

(Choices B and C) Unlike glucocorticoids, azathioprine has no adverse effects on glucose or lipid metabolism, an advantage of this medication over chronic glucocorticoid therapy.

(Choice D) Azathioprine has no known effect on lung function. The chemotherapeutic agent bleomycin may cause pulmonary fibrosis and therefore requires periodic monitoring of pulmonary function.

(Choice E) The anemia caused by azathioprine and other antimetabolite drugs (eg, methotrexate) is typically macrocytic (due to impaired DNA synthesis), but this macrocytic effect is independent of vitamin B_{12} levels. Proton pump inhibitors and histamine 2 blockers can disrupt absorption of vitamin B_{12} and may cause or contribute to its deficiency.

Educational objective:
Azathioprine is an immunosuppressant that functions via inhibition of purine synthesis by its pharmacologically active 6-thioguanine metabolites. In addition to the desired effect of reduced lymphocyte proliferation, the proliferation of other hematologic cell lines (eg, neutrophils, erythrocytes, platelets) is reduced, leading to a common adverse effect of pancytopenia.

References

- Bone marrow toxicity caused by azathioprine in inflammatory bowel disease: 27 years of experience.

Pharmacology	Rheumatology/Orthopedics & Sports	Azathioprine
Subject	System	Topic

Copyright © UWorld. All rights reserved.

A 66-year-old postmenopausal woman comes to the office to discuss her bone densitometry results. She has a history of hypertension and has smoked a pack of cigarettes daily for 30 years. BMI is 20.1 kg/m^2. Physical examination is unremarkable. Bone densitometry reveals low bone density consistent with osteoporosis. The patient is prescribed risedronate. Repeat bone densitometry 2 years later reveals no further loss of bone mineral density. Which of the following mechanisms most likely explains the drug's effect on bone mineral density?

A. Decreased osteocyte-mediated inhibition of bone formation

B. Decreased stimulation of receptor activator of nuclear factor kappa-B

C. Decreased urinary calcium excretion

D. Increased intestinal calcium absorption

E. Inhibition of osteoclast-mediated bone resorption

F. Stimulation of preosteoblasts to mature osteoblasts

Submit

A 66-year-old postmenopausal woman comes to the office to discuss her bone densitometry results. She has a history of hypertension and has smoked a pack of cigarettes daily for 30 years. BMI is 20.1 kg/m^2. Physical examination is unremarkable. Bone densitometry reveals low bone density consistent with osteoporosis. The patient is prescribed risedronate. Repeat bone densitometry 2 years later reveals no further loss of bone mineral density. Which of the following mechanisms most likely explains the drug's effect on bone mineral density?

A. Decreased osteocyte-mediated inhibition of bone formation (1%)

B. Decreased stimulation of receptor activator of nuclear factor kappa-B (7%)

C. Decreased urinary calcium excretion (0%)

D. Increased intestinal calcium absorption (1%)

✓ E. Inhibition of osteoclast-mediated bone resorption (87%)

F. Stimulation of preosteoblasts to mature osteoblasts (1%)

Omitted
Correct answer
E

87%
Answered correctly

02 secs
Time Spent

05/04/2020
Last Updated

Explanation

Medications for osteoporosis	
Calcium & vitamin D	• Given as needed to ensure adequate intake
Bisphosphonates	• Attach to hydroxyapatite binding sites on bone surfaces

Medications for osteoporosis	
Calcium & vitamin D	• Given as needed to ensure adequate intake
Bisphosphonates (eg, alendronate, risedronate)	• Attach to hydroxyapatite binding sites on bone surfaces • Inhibit osteoclast-mediated bone resorption
Denosumab	• Binds RANK-L & inhibits binding to RANK • Reduces differentiation & survival of osteoclasts
Recombinant PTH analog (teriparatide)	• Stimulates maturation of preosteoblasts into bone-forming osteoblasts • Increases gastrointestinal calcium absorption & renal tubular calcium reabsorption

RANK = receptor activator of nuclear factor kappa-B; **RANK-L** = RANK ligand; **PTH** = parathyroid hormone.

Bisphosphonates (eg, alendronate, risedronate) treat osteoporosis by **inhibiting osteoclast-mediated bone resorption**. They have a chemical structure similar to that of pyrophosphate and attach to hydroxyapatite binding sites on bony surfaces. Osteoclasts that resorb the bone take up the bisphosphonate and are unable to adhere to the bony surface to continue resorption. Bisphosphonates also decrease osteoclast proton production, induce osteoclast apoptosis, and decrease development/recruitment of osteoclast precursor cells. The net result is to **slow the rate of bone loss**, and some patients may experience a small increase in bone mineral density.

(Choice A) Sclerostin is a glycoprotein produced by osteocytes that inhibits osteoblast bone formation. Monoclonal antibody preparations (eg, romosozumab) that bind sclerostin reverse this effect and facilitate increased osteoblast activity.

(Choice B) Denosumab is a monoclonal antibody that decreases bone resorption by binding to the receptor activator of nuclear factor kappa-B ligand (RANK-L) and blocking the interaction between RANK-L and RANK (a receptor located on osteoclast surfaces), which is required for preosteoclast maturation to osteoclasts.

(Choices C, D, and F) Teriparatide is a recombinant formulation identical to the 34-amino-acid sequence at the N-terminal portion of endogenous parathyroid hormone (PTH). Similar to PTH, teriparatide stimulates maturation of preosteoblasts into bone-forming osteoblasts that lay down collagen and eventually mineralize the matrix. Teriparatide also increases gastrointestinal calcium absorption and renal tubular calcium

(teriparatide)	• Increases gastrointestinal calcium absorption & renal tubular calcium reabsorption

RANK = receptor activator of nuclear factor kappa-B; **RANK-L** = RANK ligand; **PTH** = parathyroid hormone.

Bisphosphonates (eg, alendronate, risedronate) treat osteoporosis by **inhibiting osteoclast-mediated bone resorption**. They have a chemical structure similar to that of pyrophosphate and attach to hydroxyapatite binding sites on bony surfaces. Osteoclasts that resorb the bone take up the bisphosphonate and are unable to adhere to the bony surface to continue resorption. Bisphosphonates also decrease osteoclast proton production, induce osteoclast apoptosis, and decrease development/recruitment of osteoclast precursor cells. The net result is to **slow the rate of bone loss**, and some patients may experience a small increase in bone mineral density.

(Choice A) Sclerostin is a glycoprotein produced by osteocytes that inhibits osteoblast bone formation. Monoclonal antibody preparations (eg, romosozumab) that bind sclerostin reverse this effect and facilitate increased osteoblast activity.

(Choice B) Denosumab is a monoclonal antibody that decreases bone resorption by binding to the receptor activator of nuclear factor kappa-B ligand (RANK-L) and blocking the interaction between RANK-L and RANK (a receptor located on osteoclast surfaces), which is required for preosteoclast maturation to osteoclasts.

(Choices C, D, and F) Teriparatide is a recombinant formulation identical to the 34-amino-acid sequence at the N-terminal portion of endogenous parathyroid hormone (PTH). Similar to PTH, teriparatide stimulates maturation of preosteoblasts into bone-forming osteoblasts that lay down collagen and eventually mineralize the matrix. Teriparatide also increases gastrointestinal calcium absorption and renal tubular calcium reabsorption, which leads to decreased urinary calcium excretion.

Educational objective:
Bisphosphonates have a chemical structure similar to that of pyrophosphate and attach to hydroxyapatite binding sites on bony surfaces to inhibit bone resorption by osteoclasts.

Pharmacology	Rheumatology/Orthopedics & Sports	Osteoporosis
Subject	System	Topic

Copyright © UWorld. All rights reserved.

A 55-year-old nurse was started on multidrug therapy 3 weeks ago to treat pulmonary tuberculosis contracted from a former patient. He comes to his primary care provider due to fatigue and low-grade fever for several days. He also has had muscle aches and severe joint pain in his elbows, wrists, and knees. The patient says, "I don't think it's the flu; I had the vaccine months ago." He has no current respiratory symptoms apart from pleuritic chest pain. The patient has no other significant past medical or family history. His examination is unremarkable. Laboratory results are as follows:

Hemoglobin	12.6 g/dL
Platelets	120,000/mm^3
Leukocytes	11,000/mm^3
Blood urea nitrogen	18 mg/dL
Creatinine	0.8 mg/dL
Anti-histone antibody	positive
Anti-nuclear antibody	positive

An abnormality in which of the following metabolic processes most likely underlies this patient's current condition?

A. Liver acetylation
B. Liver hydrolysis
C. Liver hydroxylation
D. Liver sulfate conjugation
E. Plasma hydrolysis

follows:

Hemoglobin	12.6 g/dL
Platelets	120,000/mm^3
Leukocytes	11,000/mm^3
Blood urea nitrogen	18 mg/dL
Creatinine	0.8 mg/dL
Anti-histone antibody	positive
Anti-nuclear antibody	positive

An abnormality in which of the following metabolic processes most likely underlies this patient's current condition?

A. Liver acetylation
B. Liver hydrolysis
C. Liver hydroxylation
D. Liver sulfate conjugation
E. Plasma hydrolysis
F. Unchanged excretion

Submit

follows:

Hemoglobin	12.6 g/dL
Platelets	120,000/mm^3
Leukocytes	11,000/mm^3
Blood urea nitrogen	18 mg/dL
Creatinine	0.8 mg/dL
Anti-histone antibody	positive
Anti-nuclear antibody	positive

An abnormality in which of the following metabolic processes most likely underlies this patient's current condition?

- ✓ A. Liver acetylation (65%)
- B. Liver hydrolysis (5%)
- C. Liver hydroxylation (14%)
- D. Liver sulfate conjugation (9%)
- E. Plasma hydrolysis (2%)
- F. Unchanged excretion (2%)

Omitted
Correct answer

65%
Answered correctly

09 secs
Time Spent

05/20/2020
Last Updated

Features of drug-induced lupus erythematosus	
Clinical features	• **Abrupt-onset** symptoms ○ Fever/fatigue ○ Arthralgias/arthritis ○ Rash ○ Serositis • Predilection for **slow acetylators**
Laboratory findings	• **Anti-histone antibodies** present in >95% of patients • Anti-dsDNA antibodies rarely seen (specific for systemic lupus erythematosus)
Implicated drugs	• **Procainamide** • **Hydralazine** • **Isoniazid** • Minocycline • TNF-α inhibitors (eg, etanercept)

©UWorld

This patient's clinical findings (constitutional symptoms, arthralgias, and pleuritic chest pain), **anti-histone antibodies**, and recent **isoniazid** use support the diagnosis of **drug-induced lupus erythematosus** (DILE). Unlike classic lupus, DILE typically lacks the usual cutaneous manifestations (eg, malar rash) and is rarely associated with neurologic or renal complications. Clinical improvement is rapid on discontinuation of the causative agent.

Procainamide, hydralazine, and isoniazid are metabolized via phase II **acetylation** in the liver. Hepatic expression of N-acetyltransferase is genetically determined, and patients with a slow acetylator phenotype are at greater risk of developing DILE. Patients who are slow acetylators

This patient's clinical findings (constitutional symptoms, arthralgias, and pleuritic chest pain), **anti-histone antibodies**, and recent **isoniazid** use support the diagnosis of **drug-induced lupus erythematosus** (DILE). Unlike classic lupus, DILE typically lacks the usual cutaneous manifestations (eg, malar rash) and is rarely associated with neurologic or renal complications. Clinical improvement is rapid on discontinuation of the causative agent.

Procainamide, hydralazine, and isoniazid are metabolized via phase II **acetylation** in the liver. Hepatic expression of N-acetyltransferase is genetically determined, and patients with a slow acetylator phenotype are at greater risk of developing DILE. Patients who are slow acetylators are also predisposed to isoniazid-induced peripheral neuropathy due to increased drug concentrations.

(Choice B) Liver hydrolysis is a phase I reaction in which a compound is cleaved by adding water (eg, esterase or amidase enzymes). Phase I metabolism usually precedes phase II conjugation metabolism.

(Choice C) Liver hydroxylation is a phase I oxidation transformation catalyzed by the cytochrome P450 monooxygenase system. Addition of a hydroxyl group reduces lipid solubility and facilitates excretion.

(Choice D) Liver sulfate conjugation is a phase II metabolic pathway that biotransforms drugs into more polar compounds that are more water soluble and easily excreted.

(Choice E) Certain drugs are hydrolyzed by plasma esterases, which rapidly cleave ester linkages after the drug enters the circulation. This rapid inactivation allows for the short duration of action of these medications. Many drugs used in anesthesia (eg, succinylcholine, tetracaine, remifentanil) are metabolized by plasma hydrolysis.

(Choice F) A few drugs are not metabolized in the body. They are excreted in the urine mostly unchanged and are still pharmacologically active.

Educational objective:
Drug-induced lupus erythematosus (DILE) is characterized by abrupt onset of lupus symptoms (eg, fever, arthralgias, pleuritis) with positive anti-histone antibodies. It has been linked to drugs metabolized by N-acetylation in the liver (eg, procainamide, hydralazine, isoniazid). Genetically predisposed individuals who are slow acetylators are at greater risk for developing DILE.

Pharmacology	Rheumatology/Orthopedics & Sports	SLE
Subject	System	Topic

A 45-year-old woman comes to the office for follow-up of arthritis. For the last year, she has had fatigue, weight loss, and progressive joint pain in the hands associated with prolonged morning stiffness. Past medical history includes hypothyroidism, for which she takes levothyroxine. The patient does not use tobacco or alcohol. Examination shows doughy swelling involving multiple metacarpophalangeal joints in both hands. Following initial diagnostic testing, a multidrug treatment regimen is started. Soon after treatment begins, she develops painful mouth ulcers and nausea. Liver function tests show new aspartate transaminase and alanine transaminase elevations. Which of the following medications is most likely responsible for the adverse effects seen in this patient?

A. Hydroxychloroquine

B. Methotrexate

C. Minocycline

D. Naproxen

E. Prednisone

Submit

A 45-year-old woman comes to the office for follow-up of arthritis. For the last year, she has had fatigue, weight loss, and progressive joint pain in the hands associated with prolonged morning stiffness. Past medical history includes hypothyroidism, for which she takes levothyroxine. The patient does not use tobacco or alcohol. Examination shows doughy swelling involving multiple metacarpophalangeal joints in both hands. Following initial diagnostic testing, a multidrug treatment regimen is started. Soon after treatment begins, she develops painful mouth ulcers and nausea. Liver function tests show new aspartate transaminase and alanine transaminase elevations. Which of the following medications is most likely responsible for the adverse effects seen in this patient?

- A. Hydroxychloroquine (11%)
- ✓ B. Methotrexate (72%)
- C. Minocycline (2%)
- D. Naproxen (6%)
- E. Prednisone (7%)

Omitted
Correct answer
B

72%
Answered correctly

02 secs
Time Spent

07/01/2020
Last Updated

Explanation

This patient, a middle-aged woman with polyarthritis, morning stiffness, and systemic symptoms, has typical features of **rheumatoid arthritis** (RA). **Methotrexate** is the preferred first-line disease-modifying treatment for most patients with moderate to severe RA. Methotrexate is a folate antimetabolite that halts purine and pyrimidine synthesis through competitive inhibition of dihydrofolate reductase.

Methotrexate preferentially inhibits growth of rapidly dividing cells, such as inflammatory and neoplastic cells. However, this inhibitory effect also

This patient, a middle-aged woman with polyarthritis, morning stiffness, and systemic symptoms, has typical features of **rheumatoid arthritis** (RA). **Methotrexate** is the preferred first-line disease-modifying treatment for most patients with moderate to severe RA. Methotrexate is a folate antimetabolite that halts purine and pyrimidine synthesis through competitive inhibition of dihydrofolate reductase.

Methotrexate preferentially inhibits growth of rapidly dividing cells, such as inflammatory and neoplastic cells. However, this inhibitory effect also causes toxicity to tissues with rapid cellular turnover, such as oral and gastrointestinal mucosa (**ulcerations**), hair follicles (alopecia), and bone marrow (pancytopenia). Methotrexate can also cause **hepatotoxicity** (hepatitis, fibrosis, cirrhosis) and pulmonary fibrosis.

(Choice A) Hydroxychloroquine is a well-tolerated antirheumatic drug used in mild RA and systemic lupus erythematosus. Its most significant toxicity is irreversible retinopathy, and patients should have regular ophthalmologic examinations.

(Choice C) Minocycline is a tetracycline antibiotic with weak antirheumatic activity. Common side effects include photosensitivity dermatitis.

(Choice D) Nonsteroidal anti-inflammatory drugs (NSAIDs [eg, naproxen]) are used for initial symptom relief in RA, although they do not prevent the long-term joint damage caused by the disease. Significant side effects include gastritis/gastric ulcers and acute kidney injury.

(Choice E) Glucocorticoids are used for initial treatment and acute flares of RA. Short-term side effects include insomnia and hyperglycemia. Long-term side effects are significant and include weight gain, osteoporosis, and muscle weakness; these drugs also potentiate the risk of gastric ulcers in patients taking NSAIDs.

Educational objective:
Methotrexate is the preferred disease-modifying treatment for patients with moderate to severe rheumatoid arthritis. Significant adverse effects include stomatitis, bone marrow suppression, and liver function abnormalities.

References

- Methotrexate for treating rheumatoid arthritis.

Pharmacology	Rheumatology/Orthopedics & Sports	Rheumatoid arthritis
Subject	System	Topic

Copyright © UWorld. All rights reserved.

A 48-year-old man comes to the office due to several hours of severe right knee pain. The patient has a history of peptic ulcer disease and gastroesophageal reflux disease. His right knee is swollen, erythematous, and tender. Arthrocentesis is performed and synovial fluid analysis shows needle-shaped, negatively birefringent crystals with many neutrophils. The medication given to this patient selectively binds to an interleukin-1 inducible enzyme that is highly expressed by inflammatory cells and undetectable in the surrounding normal tissue. Which of the following is most likely the drug used in this patient's treatment?

A. Aspirin
B. Celecoxib
C. Colchicine
D. Infliximab
E. Prednisone

Submit

A 48-year-old man comes to the office due to several hours of severe right knee pain. The patient has a history of peptic ulcer disease and gastroesophageal reflux disease. His right knee is swollen, erythematous, and tender. Arthrocentesis is performed and synovial fluid analysis shows needle-shaped, negatively birefringent crystals with many neutrophils. The medication given to this patient selectively binds to an interleukin-1 inducible enzyme that is highly expressed by inflammatory cells and undetectable in the surrounding normal tissue. Which of the following is most likely the drug used in this patient's treatment?

A. Aspirin (3%)
✓ B. Celecoxib (39%)
C. Colchicine (20%)
D. Infliximab (24%)
E. Prednisone (12%)

Omitted
Correct answer
B

39%
Answered correctly

01 sec
Time Spent

02/03/2020
Last Updated

Explanation

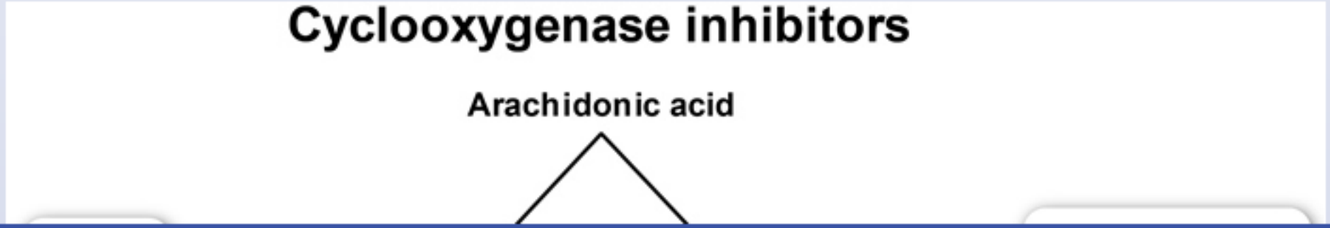

Explanation

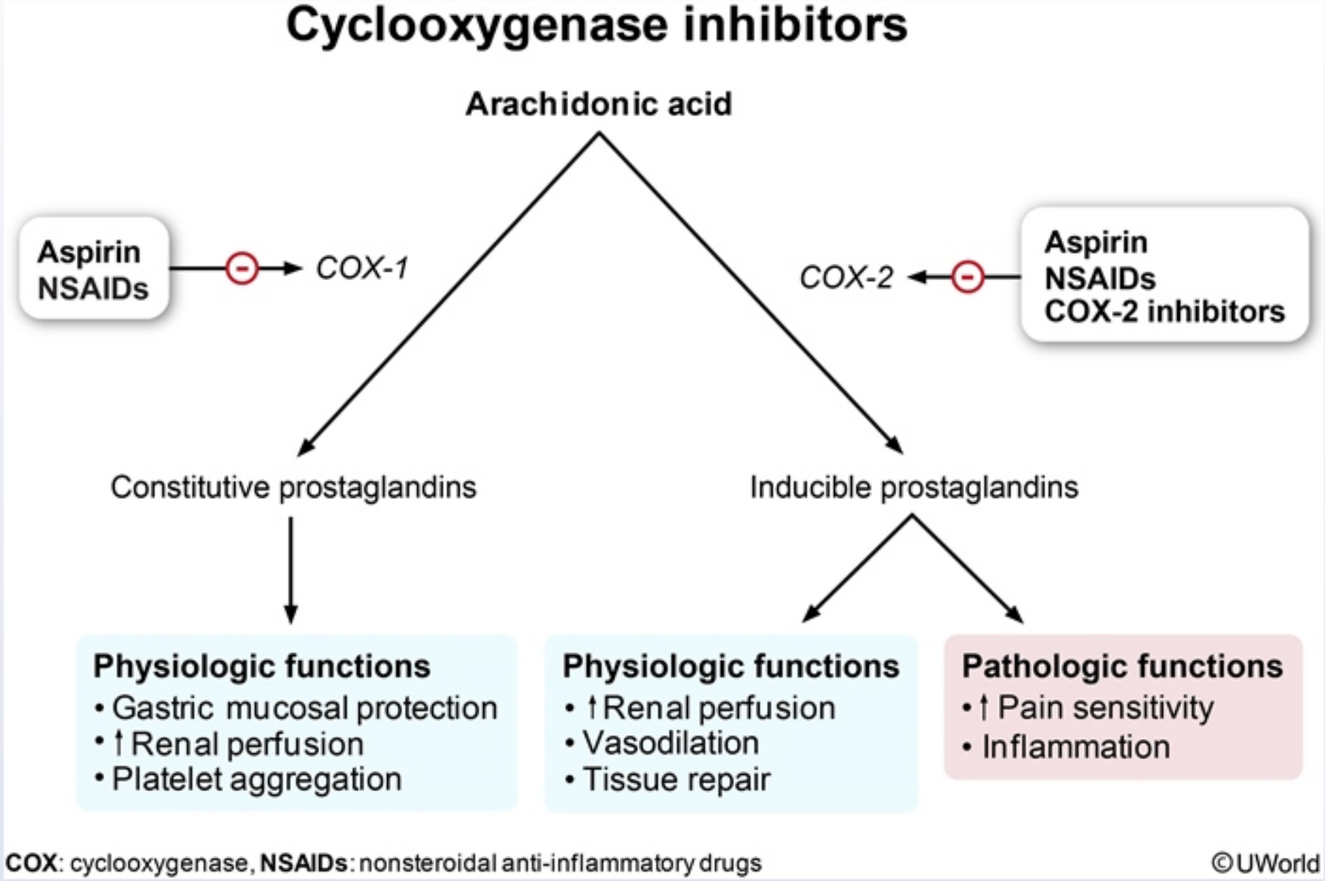

Cyclooxygenase (COX), also known as prostaglandin endoperoxide synthase, catalyzes the conversion of arachidonic acid into prostanoids. It exists in 2 isoforms designated COX-1 and COX-2. COX-1 is constitutively expressed in various tissues and is involved in a number of "housekeeping functions" (eg, platelet aggregation, gastric mucosal protection, vascular homeostasis). **COX-2** is an **inducible** enzyme that is undetectable in most tissues under normal conditions. During **inflammation**, infiltrating cells secrete cytokines (eg, **interleukin-1**, **TNF-α**) that cause COX-2 upregulation in the inflamed tissue. COX-2 then drives the synthesis of pro-inflammatory arachidonic acid metabolites.

Cyclooxygenase (COX), also known as prostaglandin endoperoxide synthase, catalyzes the conversion of arachidonic acid into prostanoids. It exists in 2 isoforms designated COX-1 and COX-2. COX-1 is constitutively expressed in various tissues and is involved in a number of "housekeeping functions" (eg, platelet aggregation, gastric mucosal protection, vascular homeostasis). **COX-2** is an **inducible** enzyme that is undetectable in most tissues under normal conditions. During **inflammation**, infiltrating cells secrete cytokines (eg, **interleukin-1**, **TNF-α**) that cause COX-2 upregulation in the inflamed tissue. COX-2 then drives the synthesis of pro-inflammatory arachidonic acid metabolites.

This patient's acute gout attack should be treated with an agent that provides prompt pain relief without exacerbating his gastrointestinal problems. Nonsteroidal anti-inflammatory drugs (NSAIDs) such as ibuprofen, indomethacin, and naproxen inhibit both COX-1 and COX-2 and can cause significant gastrointestinal injury. Selective **COX-2 inhibitors** (eg, celecoxib) decrease inflammation but have no effect on COX-1, minimizing gastroduodenal toxicity.

(Choice A) Like other NSAIDs, aspirin nonselectively inhibits both COX-1 and COX-2. Aspirin irreversibly modifies these enzymes; therefore, restoration of enzymatic activity requires synthesis of new enzymes.

(Choice C) Colchicine binds to tubulin, which inhibits microtubule formation. This results in impaired neutrophil mitosis and decreased neutrophil chemotaxis.

(Choice D) Infliximab is a monoclonal antibody that irreversibly binds to and inhibits TNF-α, a cytokine involved in the inflammatory response. TNF-α is an intercellular signaling protein, not an enzyme.

(Choice E) Glucocorticoids (eg, prednisone) bind to cytoplasmic receptors that then translocate to the nucleus where the expression of anti-inflammatory peptides is upregulated. Glucocorticoids decrease COX-2 transcription but do not bind to COX-2 directly.

Educational objective:
Cyclooxygenase-2 (COX-2) is an inducible enzyme upregulated during inflammation by interleukin-1 and TNF-α. Selective COX-2 inhibitors (eg, celecoxib) decrease inflammation by inhibiting COX-2 production of pro-inflammatory arachidonic acid metabolites. Because they do not affect COX-1, they have minimal gastroduodenal toxicity.

References

- Prostaglandins and inflammation.

Pharmacology Rheumatology/Orthopedics & Sports NSAIDs

A 58-year-old woman comes to the office with left knee pain. The pain began a year ago and has progressively become more severe. The pain is worse later in the day and is now limiting her normal day-to-day activities. She has no history of injury to the joint and has no significant pain in any other joints. The patient has attempted treatment with acetaminophen, but that has not provided adequate relief. She does not use tobacco, alcohol, or illicit drugs and works as a school bus driver. Her BMI is 34 kg/m^2. Left knee joint examination shows a mild effusion, crepitus on movement, and joint line tenderness. The patient is started on celecoxib therapy. The presence of which of the following conditions in this patient's medical history would make this medication the preferred treatment?

A. Hyperlipidemia

B. Hypertension

C. Peptic ulcer disease

D. Renal impairment

E. Stable angina

Submit

A 58-year-old woman comes to the office with left knee pain. The pain began a year ago and has progressively become more severe. The pain is worse later in the day and is now limiting her normal day-to-day activities. She has no history of injury to the joint and has no significant pain in any other joints. The patient has attempted treatment with acetaminophen, but that has not provided adequate relief. She does not use tobacco, alcohol, or illicit drugs and works as a school bus driver. Her BMI is 34 kg/m^2. Left knee joint examination shows a mild effusion, crepitus on movement, and joint line tenderness. The patient is started on celecoxib therapy. The presence of which of the following conditions in this patient's medical history would make this medication the preferred treatment?

- A. Hyperlipidemia (3%)
- B. Hypertension (1%)
- ✓ C. Peptic ulcer disease (83%)
- D. Renal impairment (7%)
- E. Stable angina (3%)

Omitted
Correct answer
C

83%
Answered correctly

01 sec
Time Spent

05/04/2020
Last Updated

Explanation

Cyclooxygenase inhibitors

Arachidonic acid

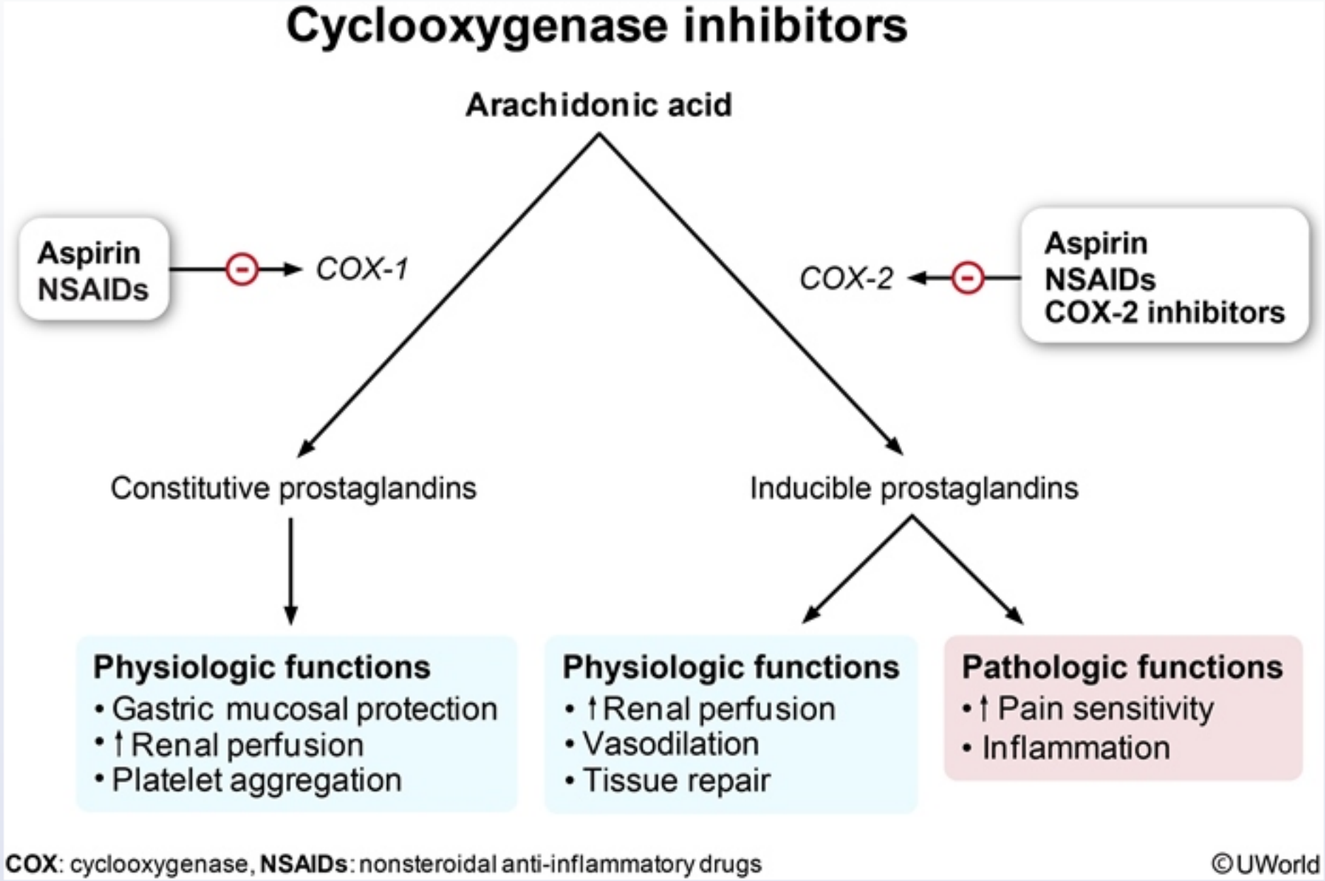

Cyclooxygenase (COX; prostaglandin synthase) initiates the synthesis of prostanoids (eg, prostaglandins, thromboxane) from arachidonic acid. COX exists in 2 primary forms:

- COX 1, which plays a physiologic role in a number of normally functioning tissues (eg, platelets, gastrointestinal tract)
- COX 2, which is preferentially expressed at sites of inflammation.

Nonsteroidal anti-inflammatory drugs (NSAIDs) work by inhibiting COX to block prostaglandin synthesis. Most NSAIDs inhibit both the COX 1

- COX 1, which plays a physiologic role in a number of normally functioning tissues (eg, platelets, gastrointestinal tract)
- COX 2, which is preferentially expressed at sites of inflammation.

Nonsteroidal anti-inflammatory drugs (NSAIDs) work by inhibiting COX to block prostaglandin synthesis. Most NSAIDs inhibit both the COX 1 and COX 2 isoenzymes. However, inhibition of COX 1 may lead to severe adverse effects, including **gastric ulceration** (reduced mucosal protection) and **increased bleeding** (decreased platelet aggregation). Selective **COX 2 inhibitors** (eg, celecoxib) have potent anti-inflammatory effects with **less risk** of bleeding and gastrointestinal ulceration. They are recommended for use in patients at risk for gastrointestinal complications, such as those with prior peptic ulcer disease. The risk for ulcers can also be reduced by combining a nonselective NSAID with a second drug (eg, proton pump inhibitors, misoprostol) to reduce gastric acid secretion.

(Choice A) Selective COX 2 inhibitors do not have a substantial effect on serum lipids.

(Choices B and D) Both COX 1 and COX 2 are expressed in renal tissues. Therapy with either nonselective NSAIDs or selective COX 2 inhibitors can cause fluid retention, aggravation of hypertension, and impaired renal function.

(Choice E) COX 2 is expressed in vascular endothelial cells and vascular smooth muscle cells, where it plays a role in the local production of prostacyclin, which has anticoagulant and vasodilatory actions. COX 2 inhibitors have been associated with an increased risk of cardiovascular events.

Educational objective:
Selective cyclooxygenase 2 (COX 2) inhibitors relieve pain with lower risk of bleeding and gastric ulceration than nonselective nonsteroidal anti-inflammatory drugs.

References

- Comparison of gastrointestinal adverse effects between cyclooxygenase-2 inhibitors and non-selective, non-steroidal anti-inflammatory drugs plus proton pump inhibitors: a systematic review and meta-analysis.

Pharmacology	Rheumatology/Orthopedics & Sports	Cox 2 inhibitor
Subject	System	Topic

Copyright © UWorld. All rights reserved.

A 54-year-old man comes to the office due to severe foot pain. The patient attended a wedding reception where he drank several alcoholic beverages, then woke the following morning with pain. He has a long history of gouty arthritis, and his current symptoms are similar to previous flares of the disease. Past medical history includes type 2 diabetes mellitus and recently diagnosed peptic ulcer disease. Physical examination shows erythema, warmth, and swelling at the left first metatarsophalangeal joint. The patient is started on a new medication for gout that provides significant relief of his symptoms, but he returns to the clinic a week later with diarrhea and persistent nausea. The drug used in this patient most likely affects which of the following cell structures?

- A. Cytoskeleton
- B. Golgi apparatus
- C. Microsomes
- D. Nucleus
- E. Peroxisomes
- F. Rough endoplasmic reticulum
- G. Smooth endoplasmic reticulum

Submit

A 54-year-old man comes to the office due to severe foot pain. The patient attended a wedding reception where he drank several alcoholic beverages, then woke the following morning with pain. He has a long history of gouty arthritis, and his current symptoms are similar to previous flares of the disease. Past medical history includes type 2 diabetes mellitus and recently diagnosed peptic ulcer disease. Physical examination shows erythema, warmth, and swelling at the left first metatarsophalangeal joint. The patient is started on a new medication for gout that provides significant relief of his symptoms, but he returns to the clinic a week later with diarrhea and persistent nausea. The drug used in this patient most likely affects which of the following cell structures?

- ✓ A. Cytoskeleton (75%)
- B. Golgi apparatus (1%)
- C. Microsomes (5%)
- D. Nucleus (6%)
- E. Peroxisomes (5%)
- F. Rough endoplasmic reticulum (3%)
- G. Smooth endoplasmic reticulum (1%)

Omitted
Correct answer
A

75%
Answered correctly

02 secs
Time Spent

03/30/2020
Last Updated

Explanation

The preferred first-line treatment for acute gouty arthritis is a nonsteroidal anti-inflammatory drug, but these are contraindicated in patients with a

Omitted
Correct answer
A

75%
Answered correctly

02 secs
Time Spent

03/30/2020
Last Updated

Explanation

The preferred first-line treatment for acute gouty arthritis is a nonsteroidal anti-inflammatory drug, but these are contraindicated in patients with a recent history of peptic ulcer. Other treatment options include colchicine and oral or intraarticular glucocorticoids.

Colchicine binds to the intracellular protein **tubulin** and inhibits its polymerization into microtubules. This, in turn, disrupts cytoskeletal-dependent functions such as chemotaxis and phagocytosis. Colchicine is administered initially at the first signs of a gout flare and can be repeated an hour later. It may also be used for prophylaxis while initiating urate-lowering therapy (eg, allopurinol). Important adverse effects of colchicine include nausea, abdominal pain, and **diarrhea**, which are most common at higher doses. Colchicine should be avoided in patients who are elderly or have severe renal dysfunction.

Educational objective:
Colchicine inhibits tubulin polymerization into microtubules and can be used for acute treatment and prophylaxis of gout. Important side effects of colchicine include nausea, abdominal pain, and diarrhea.

References

- Colchicine for acute gout.

Pharmacology	Rheumatology/Orthopedics & Sports	Gout
Subject	System	Topic

Copyright © UWorld. All rights reserved.